

# Oxford® Partial Knee

Microplasty® Instrumentation

Surgical Technique





# Table of Contents

|  |    |
|--|----|
| <b>Oxford Partial Knee</b> .....                           | 2  |
| Femoral Components.....                                    | 2  |
| Tibial Components .....                                    | 2  |
| Meniscal Bearings .....                                    | 2  |
| <b>Patient Selection</b> .....                             | 3  |
| The Learning Curve .....                                   | 4  |
| Preoperative X-ray Template.....                           | 5  |
| Open vs. Minimally Invasive Technique.....                 | 6  |
| <b>Surgical Technique</b> .....                            | 7  |
| Positioning the Limb.....                                  | 7  |
| Incision .....   | 7  |
| Osteophyte Excision.....                                   | 8  |
| Tibial Plateau Resection.....                              | 9  |
| The Femoral Drill Holes and Alignment.....                 | 12 |
| Femoral Saw Cut .....                                      | 14 |
| First Milling of the Condyle .....                         | 16 |
| Equalizing the Flexion and Extension Gaps .....            | 17 |
| Confirming Equality of the Flexion and Extension Gaps..... | 19 |
| Preventing Impingement.....                                | 20 |
| Final Preparation of the Tibial Plateau .....              | 22 |
| Final Trial Reduction .....                                | 24 |
| Cementing the Components .....                             | 26 |
| <b>Appendix</b> .....                                      | 30 |
| Postoperative Treatment .....                              | 30 |
| Postoperative Radiographic Assessment .....                | 30 |
| Radiographic Technique .....                               | 30 |
| Radiographic Criteria.....                                 | 31 |
| Position and Size of Components.....                       | 31 |
| Follow-up Radiographs.....                                 | 32 |
| <b>Ordering Information</b> .....                          | 33 |
| <b>Indications and Full Prescribing Information</b> .....  | 52 |

## Oxford Partial Knee

### Introduction

The Oxford Partial Knee is the natural evolution of the original meniscal arthroplasty, which was first used in 1976.<sup>1</sup> Its design continues to offer the advantage of a large area of contact throughout the entire range of movement for minimal polyethylene wear, as seen in the Oxford Partial Knee Phase I and II.<sup>2,3</sup>

Since 1982, the Oxford Partial Knee has been successfully used to treat anteromedial osteoarthritis.<sup>4-5</sup> If performed early in this disease process, the operation can slow the progression of arthritis in the other compartments of the joint and provide long-term symptom relief.<sup>5</sup>

The Oxford implant is based on its clinically successful predecessors (Phase I and Phase II) which achieved survivorship rates of 98% at 10 years,<sup>5,7</sup> with an average wear rate of 0.03 mm per year.<sup>2,3</sup>

### Femoral Components

The unique, spherically designed femoral components are made of cast cobalt chromium molybdenum alloy for strength, wear resistance and biocompatibility. The design is available in five sizes to provide an optimal fit. The sizes are parametric and have corresponding radii of curvature.

The articulating surface of the femoral component is spherical and polished to a very high tolerance. The appropriate size of femoral component is chosen based on the patient size, preoperative templating of lateral radiographs and intraoperative measurement confirmed with sizing spoons.

### Tibial Components

The tibial components, also made of cast cobalt chromium molybdenum alloy, are available in seven sizes, both right and left. Their shapes are designed to provide optimal bone coverage, while avoiding component overhang anteromedially.

### Meniscal Bearings

The bearings are direct compression molded ultra-high molecular weight polyethylene (UHMWPE), manufactured from ArCom<sup>®</sup> Direct Compression Molded Polyethylene for increased wear resistance.<sup>8,9</sup>

There are five bearing sizes to match the radii of curvature of the five femoral component sizes. For each size, there is a range of seven thicknesses, from 3 mm to 9 mm.

## Patient Selection

There are well-defined circumstances in which the Oxford Partial Knee for medial arthroplasty is appropriate, and certain criteria must be fulfilled for success:

- The operation is indicated for the treatment of anteromedial osteoarthritis.<sup>4</sup>

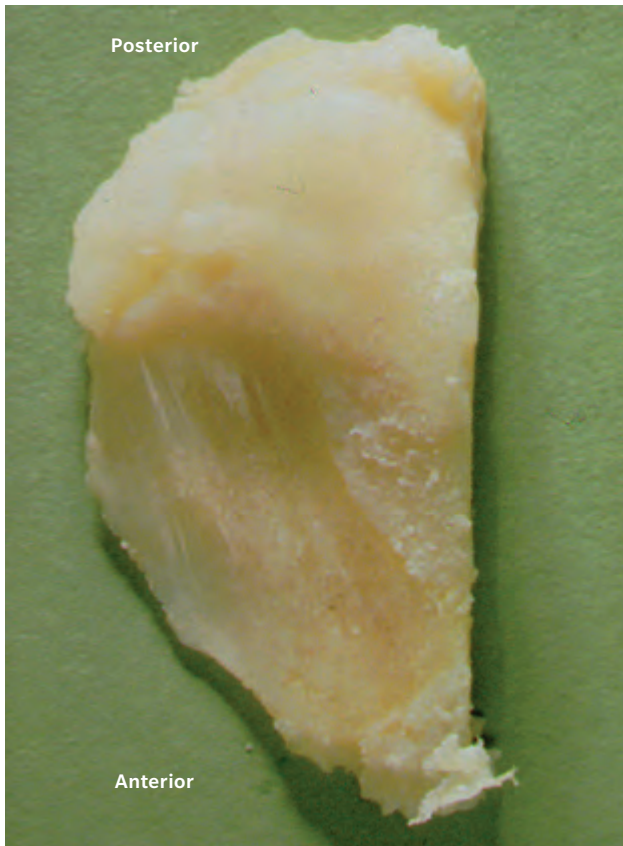

Figure 1

- There must be full thickness cartilage loss on both sides of the medial compartment with bone on bone contact (Figure 1). This may be demonstrated radiographically (weight bearing A/P, Rosenberg or varus stress) or arthroscopically. The results of replacement for partial thickness cartilage loss are unpredictable.<sup>10</sup>
- Both cruciate ligaments must be functionally intact. The posterior cruciate is seldom diseased in osteoarthritic knees, but the anterior cruciate is often damaged and is sometimes absent. This deficiency is a contraindication to the procedure.

- Posterior bone loss on a lateral radiograph or mediolateral subluxation that does not correct on valgus stress radiographs strongly suggests damage to the anterior cruciate ligament (ACL).<sup>11</sup> If there is doubt about the integrity of the ACL, it should be assessed with a hook during the operation.
- The lateral compartment should be well preserved, with an intact meniscus and full thickness of articular cartilage. This is best demonstrated by the presence of a full thickness 'joint space' visible on an A/P radiograph taken with the joint stressed into valgus.<sup>12</sup> However, a grade 1 cartilage defect, marginal osteophytes and localized areas of erosion of the cartilage on the medial side of the lateral condyle are frequently seen during surgery and are not contraindications to medial compartment arthroplasty.
- The intra-articular varus deformity must be passively correctable to pre-disease status and not beyond. A good way to confirm this is to take valgus stressed radiographs.
- The degree of intra-articular deformity is not as important as its ability to be passively corrected by the application of a valgus force. Varus deformity of more than 15 degrees can seldom be passively corrected to neutral; therefore, this figure represents the outer limit. Soft tissue release should never be performed. If the medial collateral ligament has shortened and passive correction of the varus is impossible, the arthritic process has progressed beyond the suitable stage for this procedure, and thus the procedure is contraindicated.
- Flexion deformity should be less than 15 degrees. If it is greater than 15 degrees the ACL is usually ruptured.
- The knee must be able to flex to at least 110 degrees under anesthetic to allow access for preparation of the femoral condyle.

- The state of the patellofemoral joint (PFJ) is not a contraindication provided there is not severe damage to the lateral part of the PFJ with bone loss, grooving or subluxation. Neither the presence of preoperative anterior knee pain or cartilage loss in the PFJ have been shown to compromise the outcome.<sup>13</sup> Similar arthritis in the medial part of the PFJ, however severe, or early arthritis in the lateral part of the PFJ have not compromised the outcome in reported studies.<sup>13–15</sup>
- Neither the patient’s age, weight nor activity level are contraindications, nor is the presence of chondrocalcinosis.<sup>14–16</sup>
- Unicompartmental arthroplasty is contraindicated in all forms of inflammatory arthritis. (The pathological changes of early rheumatoid arthritis can be confused with those of medial compartment osteoarthritis). The high success rates reported<sup>5,7</sup> were achieved in patients with anteromedial osteoarthritis, and they may not be achieved with other diagnoses. The Oxford Implant has also been used successfully in the treatment of primary avascular necrosis, which has been included as a main indication for use of the Oxford Partial Knee.<sup>18</sup>
- The Oxford medial arthroplasty is not designed for and is contraindicated for lateral compartment replacement. The ligaments of the lateral compartment are more elastic than those of the medial, and early dislocation of the bearing has been reported. Access through a small incision is more difficult laterally than medially. The Vanguard M™ series fixed bearing unicompartmental replacement is an available option for lateral compartment arthroplasty.
- The final decision whether or not to perform unicompartmental arthroplasty is made when the knee has been opened and directly inspected.

## The Learning Curve

This surgical technique should be used in association with the instructional video of the operation. As with other surgical procedures, errors of technique are more likely when the method is being learned. **To reduce these to a minimum, surgeons are required by the FDA in the United States, and strongly recommended throughout the world, to attend an Advanced Instructional Course on the Oxford Partial Knee before attempting the operation. Masters Courses are also offered to enhance skills through round-table discussions, technical tips, surgical issues, case studies and presentations.**

## Preoperative X-ray Template

The size of femoral component can be chosen preoperatively using X-ray templates (Figure 2). A true lateral radiograph is required to accurately template.

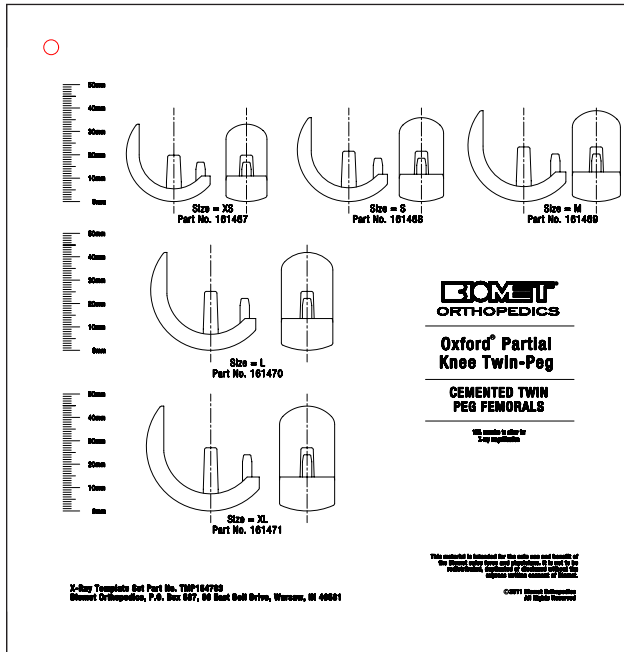


Figure 2

Available templates allow for magnification of 105 and 115 percent. To achieve this the patient should lie on their side with the affected knee resting against the X-ray plate and the X-ray tube being about 1 m away.

Apply the outlines on the template to the X-ray image of the medial femoral condyle. The line along the central peg of the implant should be 10 degrees flexed compared to the long axis of the femoral shaft. The outer surface of the diagrammatic component should lie about 2 mm outside the radiographic image to allow for the thickness of articular cartilage. For a correctly sized implant the proximal part of the prosthesis should be approximately 2 mm outside the bone surface of the proximal part of the condyle so the implant surface and retained proximal cartilage are flush (Figure 3).

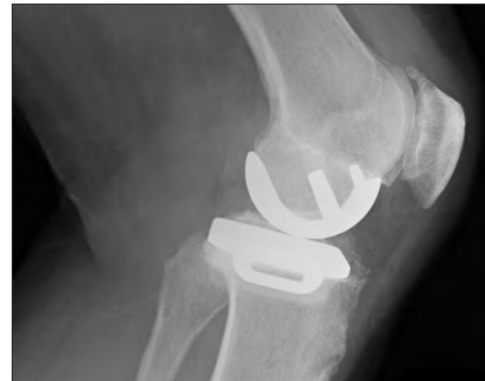

Figure 3

A medium size femoral component is appropriate for most patients. In fact, it was the only size used in the Phase I and II implants.

However, the small size is typically utilized for small women (typically less than 5 ft 5 in, 165 cm tall) and the large size in large men (typically more than 5 ft 7 in, 170 cm tall).<sup>19</sup> The extra large is only needed in very large men and the extra small in very small women. If there is doubt between small/medium or medium/large, it is usually best to use the medium. The extra small should only be used in very small women.

## Open vs. Minimally Invasive Technique

One advantage of PKA is that it can be performed through a small incision without dislocating the patella, thus avoiding damage to the synovial reflections of the suprapatellar pouch. This can reduce postoperative pain and allow a more complete and rapid recovery of flexion. With proper use of the Oxford Partial Knee instrumentation, the operation can be performed through a small incision with great precision. However, surgeons learning the procedure can extend the soft tissue incision beyond the limits described here with very little increase in postoperative morbidity as long as the integrity of the suprapatellar pouch is preserved.

The open approach, with dislocation of the patella, is not recommended. The Oxford Partial Knee instrumentation is designed for use through a small incision, and intraoperative dislocation of the patella distorts the ligaments, possibly making the operation more difficult.



## Surgical Technique

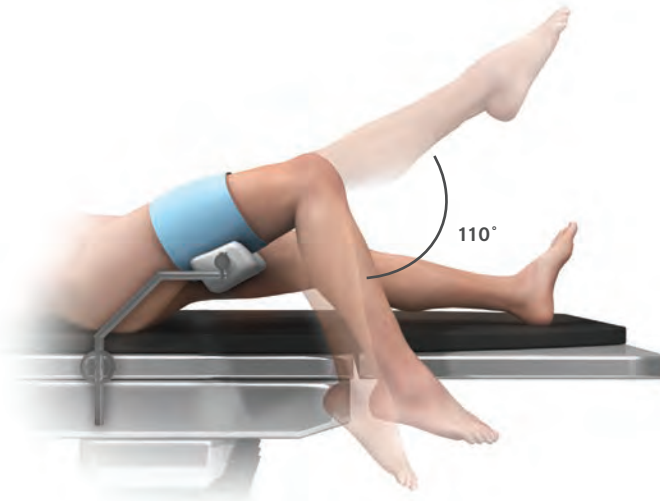


Figure 4

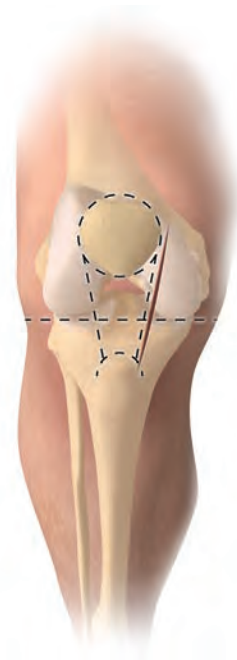


Figure 5

### Positioning the Limb

Inflate a thigh tourniquet and place the draped leg on a thigh support, with the hip flexed to about 30 degrees and the leg dependent. The knee must be free to flex fully and the leg should hang with the knee flexed about 110 degrees (Figure 4). The thigh support must not be placed in the popliteal fossa as this will increase the risk of damage to the popliteal vessels.

### Incision

With the knee flexed to 90 degrees, make a medial parapatellar skin incision from the medial margin of the patella to a point 3 cm distal to the joint line (Figure 5). Deepen the incision through the joint capsule. At its upper end, the capsular incision should extend proximally about 2 cm into the vastus medialis. It should pass around the patella and down beside the patella tendon.

Expose the front of the tibia in the lower part of the wound from the tibial tubercle to the anteromedial rim of the plateau. Excise as much of the medial meniscus as possible. Do not 'release' any of the fibers of the medial collateral ligament.

Surgeons who are learning the technique should make a larger incision to improve the exposure. The patella should be subluxed but not dislocated.

Excise part of the retropatellar fat pad and insert retractors into the synovial cavity. The ACL can now be inspected to ascertain that it is intact. (Absence of a functioning ACL is a contraindication. If this is found, the operation should be abandoned in favor of a total knee replacement).

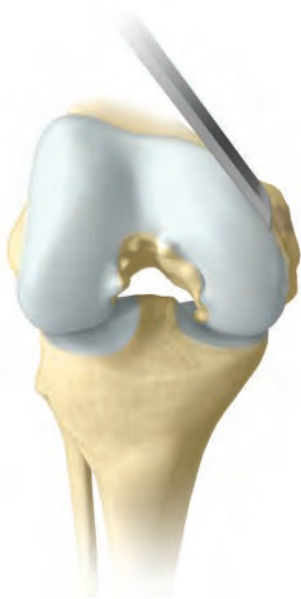

Figure 6

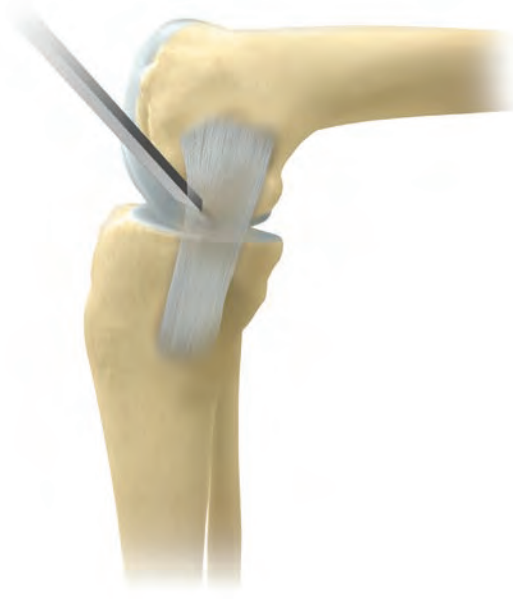

Figure 7

## Osteophyte Excision

All osteophytes must be removed from the medial margin of the medial femoral condyle and from both margins of the intercondylar notch (Figure 6). The assistant extends and flexes the knee, moving the incision up and down, allowing the various osteophytes to come into view. Osteophytes on the tibial plateau in front of the insertion of the ACL and in the top of the notch must be removed to allow the fixed flexion deformity to correct. If there are large osteophytes around the patella they should also be removed.

With a narrow chisel (6 mm), remove the osteophytes from beneath the medial collateral ligament (Figure 7) and from the posterolateral margin of the medial condyle. This creates room to insert the saw blade into the intercondylar notch during the next step.

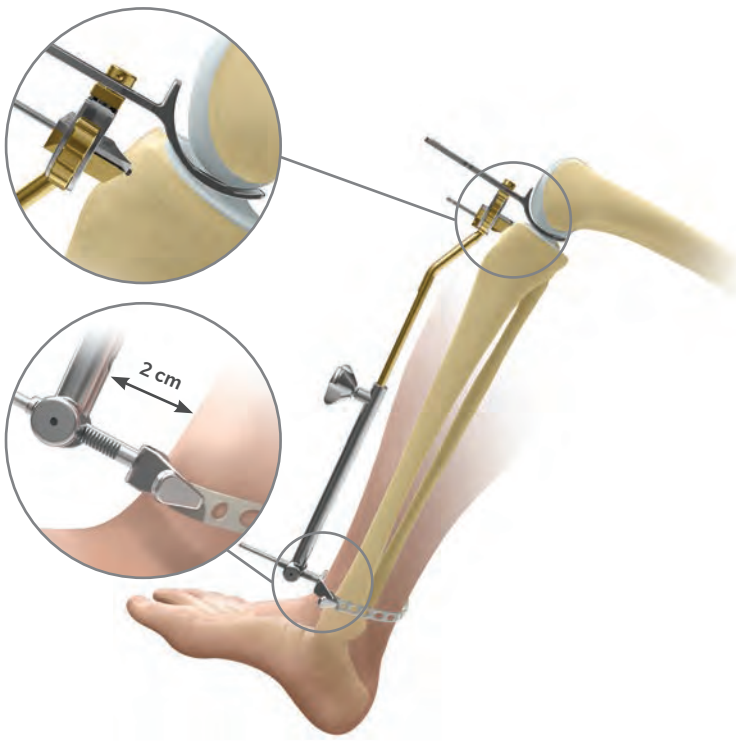


Figure 8

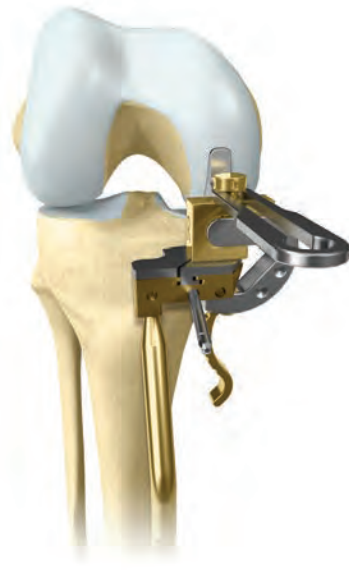

Figure 9

## Tibial Plateau Resection

With the knee in flexion, insert the femoral sizing spoon (based on preoperative estimate sizing) starting with 1 mm spoon. With all retraction removed, assess the ligament tension. Usually the 1 mm thick femoral sizing spoon achieves the proper ligament tension, but if it does not, replace it with a thicker sizing spoon until the proper tension is achieved. The optimal size of the femoral component is confirmed by examining the relationship of the front of the spoon and an estimate of where the cartilage surface would have been before the arthritis. The correct sizing spoon should be inserted centrally in the medial compartment.

Apply the tibial saw guide with its shaft parallel with the long axis of the tibia in both planes (Figures 8 and 9). The ankle piece should be pointing towards the anterior superior iliac spine and the standard 0 mm tibial shim should be used. The tibial saw guide has 7 degrees of posterior slope built in.

The femoral sizing spoon, tibial saw guide and G-clamp, when used together, will accurately establish the bony

resection. Select either the 3 or the 4 G-clamp and apply to the femoral sizing spoon and to the medial side of the tibial saw guide to ensure access to pin holes.

Manipulate the upper end of the guide so that its face lies against the exposed bone. A recess accommodates the skin and the patellar tendon laterally (Figure 9). Engage the cam, by pulling the lever downwards, to lock the three components together.

Once the G-clamp is locked holding the femoral sizing spoon and tibial saw guide in place, pin the guide.

**Note:** When pinning the guide, the two medial pin holes may be used to secure the guide utilizing one headed and one headless pin, or the single hole directly anterior to the shaft may be pinned to minimize the number of perforations in the tibial bone.

Once the tibial saw guide is pinned in place, unlock the G-clamp and remove along with the femoral sizing spoon.

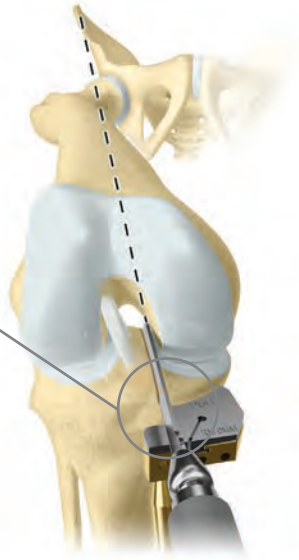
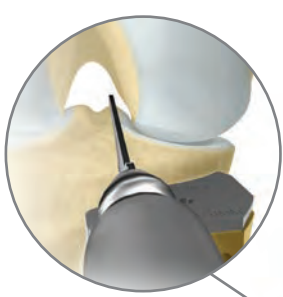


Figure 10

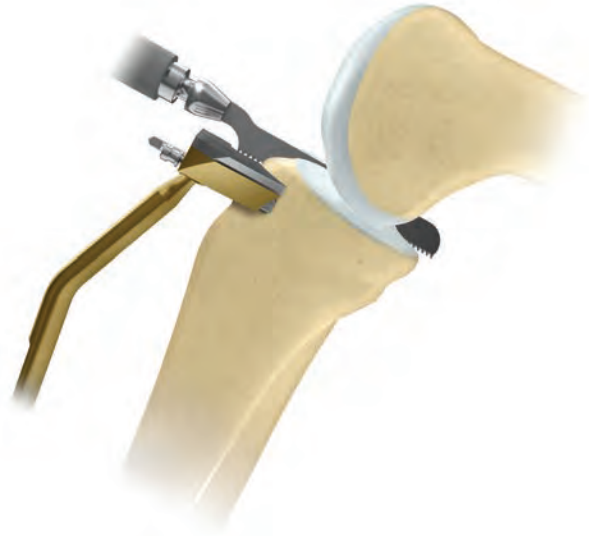

Figure 11

### Tibial Plateau Resection (cont.)

Confirm the proposed level of resection is correct. The saw cut should pass 2 or 3 mm below the deepest part of the erosion, unless the erosion is very deep in which case the cut should be above the bottom of the defect.

Use a reciprocating saw with a stiff narrow blade to make the vertical tibial saw cut. The Oxford Saw Blade Kit contains blades with markings to indicate the depth to safely divide the posterior cortex. Push the blade into the intercondylar notch close to the lateral margin of the medial femoral condyle, from which the osteophytes were removed previously. The saw cut should be just medial to the apex of the medial tibial spine. It will pass through the edge of the ACL insertion. Point the blade toward the anterior superior iliac spine or flexion plane (Figure 10).

The saw must reach the back of the tibial plateau and a little beyond. This is achieved by lining up the appropriate mark on the saw with the anterior cortex. Advance the saw vertically down until it rests on the surface of the saw guide (Figure 11). The saw must remain parallel to the guide. Do not lift the saw handle as this will dip the saw blade and increase the risk of tibial plateau fracture.

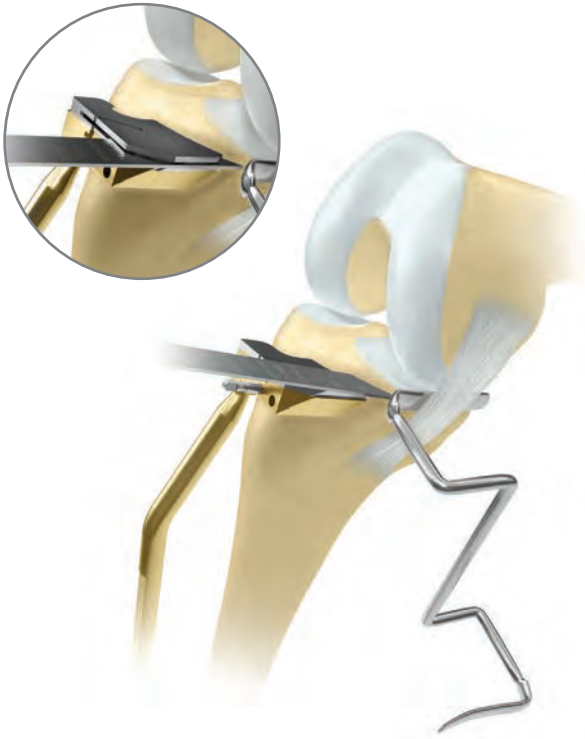

Figure 12



Figure 13

### Tibial Plateau Resection (cont.)

Before making the horizontal cut, insert a medial collateral ligament (MCL) retractor. Ensure this retractor is between the saw and the MCL.

Use a 12 mm wide oscillating saw blade with appropriate markings to excise the plateau (Figure 12). Ensure the saw blade is guided along the MCL retractor to completely cut the medial cortex. To cut the posterior cortex, deepen the cut until the appropriate mark on the saw blade is aligned with the anterior cortex. When the plateau is loose, lever it up with a broad osteotome and remove. Soft tissue attachments posteromedially may need to be cut with a knife.

ⓘ **Note:** When making the horizontal cut a slotted shim may be used. This can be done by replacing the standard shim with the corresponding slotted shim. The slotted shim helps maintain the 7 degree posterior slope during the resection.

The excised plateau should show the classical lesion of anteromedial osteoarthritis, erosion of cartilage and bone in its mid and anterior parts and preserved cartilage posteriorly (Figure 13). Osteophytes around the edge of the plateau remain attached after its removal.

Lay tibial templates of the opposite side on the cut surface of the excised plateau to choose the tibial component with the appropriate width.

If the tibial component of the appropriate width appears short, consider repeating the vertical cut 2 or 3 mm further lateral so that a wider (and longer) component may be used.

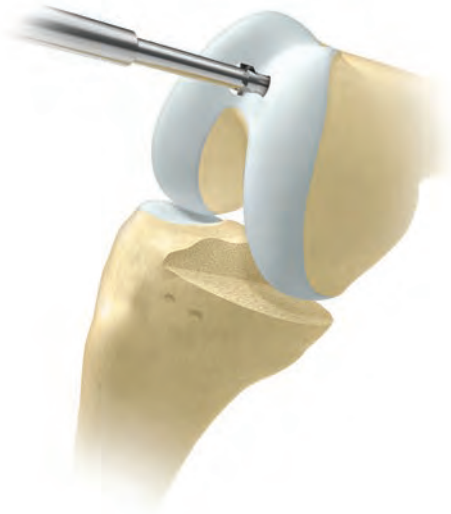

Figure 14

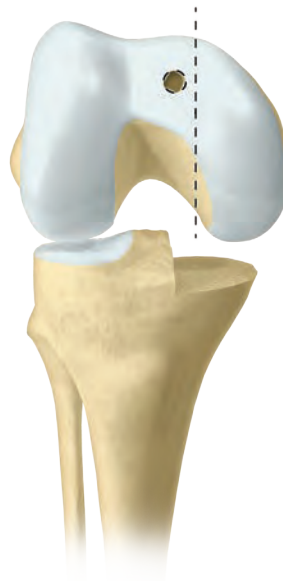

Figure 15

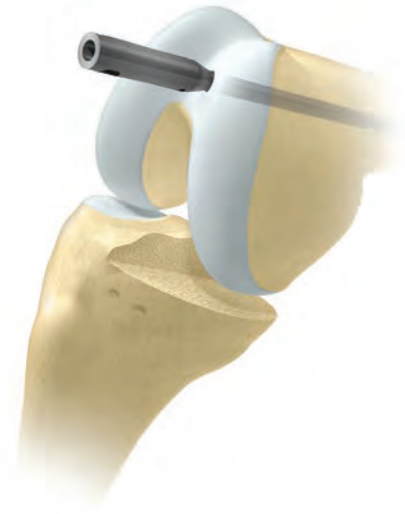

Figure 16

## The Femoral Drill Holes and Alignment

With the knee in about 45 degrees flexion, make a hole in the intramedullary canal of the femur with the 4 mm drill. This should be completed with the 5 mm awl (Figure 14).

The hole must be situated approximately 1 cm anterior to the insertion of the PCL and 2-3 mm lateral to the medial wall of the intercondylar notch (Figure 15). It should aim for the anterior superior iliac spine.

Insert the intramedullary (IM) rod until it stops against the bone (Figure 16).

Flex the knee to 90 degrees. This must be done with care, as the medial border of the patella abuts the IM rod. Using methylene blue or diathermy, draw a line down the center of the medial condyle.



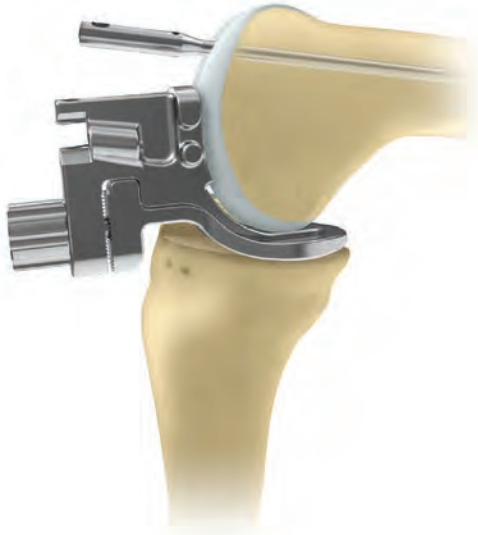

Figure 17

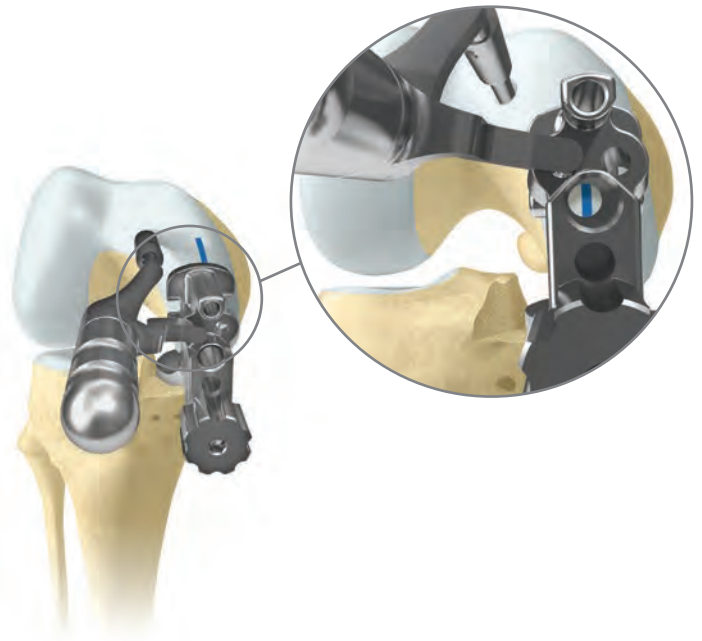

Figure 18

## The Femoral Drill Holes and Alignment (cont.)

Insert the femoral drill guide to assess the thickness of the gap (Figure 17).

The thickness of bone removed from the tibia must be enough to accommodate the femoral drill guide set at a 3 or 4. If a 3 G-clamp was used, the gap must be large enough to accept the femoral drill guide set to 3. If the 4 G-clamp was used, the gap must be large enough to accept the femoral drill guide set to 4.

**Note:** Whenever using the femoral drill guide or feeler gauges to gap measure the retractors must be removed. If left in, they have the effect of tightening the soft tissues, which artificially diminishes the gap.

If the correctly adjusted femoral drill guide cannot be inserted or feels tight, more bone must be excised from the tibia. To do this, remove the initial 0 mm shim from the guide using the small nub on the Oxford IM Rod Removal Hook. Once the shim is removed, revisit the vertical resection, then resect off the surface of the guide without the shim to remove 2 mm of additional bone. After additional resection, recheck the gap.

Insert the IM link into the IM rod and into the nearside/lateral hole of the femoral drill guide. This will ensure correct alignment of the guide.

There are two alignment requirements for the femoral drill guide:

1. The femoral drill guide must lie in the center of the medial condyle. This is done by ensuring the medial and lateral bollards adjacent to the 6 mm hole of the femoral drill guide are equal distance from the condyle edges. It can be confirmed by looking into the 6 mm hole and verifying the position of the methylene blue line. If the line is not central adjust the guide position (Figure 18).
2. The femoral drill guide must be placed against the distal bone of the medial femoral condyle.

Pass the 4 mm drill through the upper hole in the guide. Drill into the bone up to its stop and leave in place. Confirm all alignments ensuring the guide does not move medially or laterally. Advance the 6 mm drill through the lower guide hole until it stops. Remove 4 mm and 6 mm drill along with the femoral drill guide.

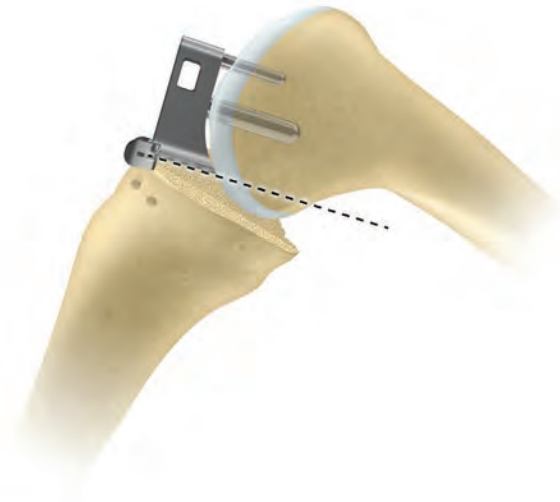

Figure 19

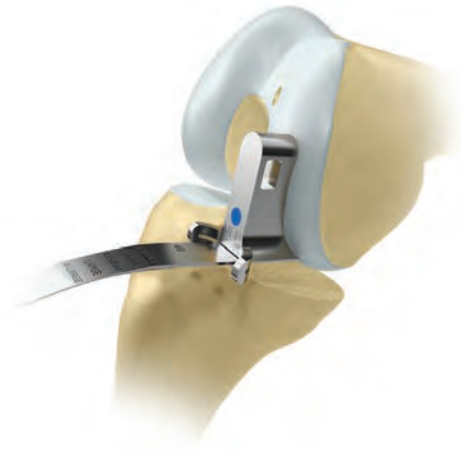

Figure 20

## Femoral Saw Cut

Insert the posterior resection guide into the drilled holes and tap home (Figure 19).

Insert a retractor to protect the MCL. Using the 12 mm broad sagittal saw, excise the posterior femoral condyle. The saw blade should be bent slightly by dropping the saw to ensure it is guided by the underside of the posterior resection guide (Figure 20). Take care to avoid damage to the medial collateral and anterior cruciate ligaments.

Remove the guide with the slap hammer, ensuring that it is withdrawn in line with the femoral drill guide holes as to not damage them. Remove the posterior bone fragment.

There is now good access to the back of the joint and any remnants of the medial meniscus should be removed. In the region of the MCL, a small cuff of meniscus should be left to protect the MCL from the tibial component. The posterior horn should be completely removed.



Before advancing to the following surgical steps, consult the special note below.

## Special Note

The numbers marked on the feeler gauges and the meniscal bearings represent their least thicknesses in millimeters.

The scale of numbers of the spigots is in 1 mm increments, in an inverse ratio to the thickness of their flanges.

The spigots must be used as described below:

- **First Milling**

The 0 spigot is designed to automatically remove sufficient bone to allow the femoral component to seat. This amount varies with the degree of arthritic erosion of the condyle.

- **Second Milling**

Spigots 1 to 7 allow bone to be removed in measured quantities (in mm) from the level of the first mill cut. Thus, the number 3 spigot removes 3 mm, the number 4 spigot removes 4 mm, etc.

- **Subsequent Milling**

If the last spigot used was a number 3, a number 4 spigot will remove an additional 1 mm of bone (i.e. a total of 4 mm since the first milling). However, if the last spigot used was a number 4, a number 5 spigot is required to remove 1 mm of bone (i.e. a total thickness of 5 mm since the first milling).

**Remember:** The spigot number represents the total thickness of bone it removes from the level of the first mill cut.

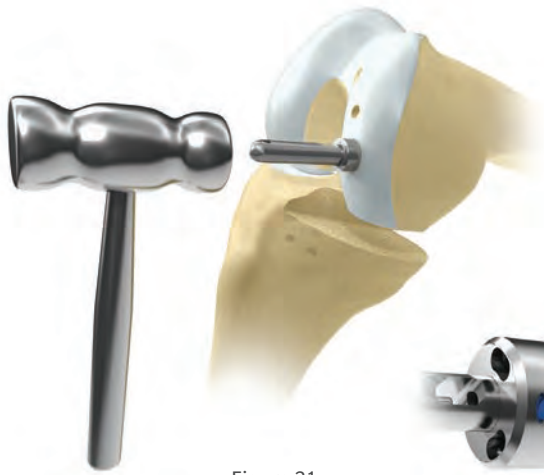

Figure 21

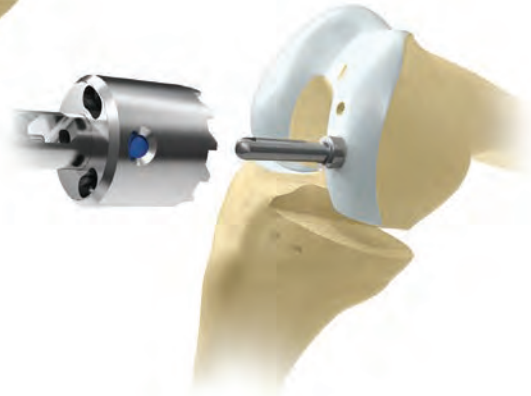


Figure 22

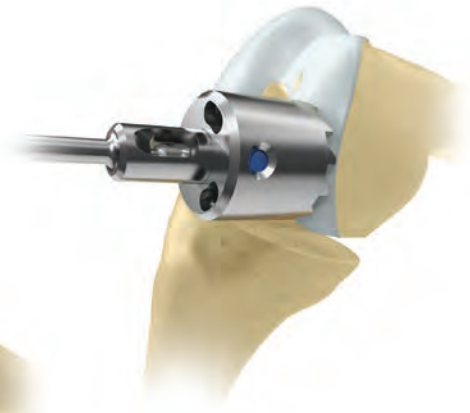

Figure 23

## First Milling of the Condyle

Insert the 0 spigot, which has the thickest flange, into the large drill hole and tap until the flange abuts the bone (Figure 21). The 0 spigot is the only spigot that may be tapped into place. All other spigots should be placed and seated by finger pressure.

By extending the knee slightly and retracting the soft tissues, maneuver the spherical cutter onto the spigot (Figure 22) and into the wound so that the teeth touch the bone (Figure 23). Take care to avoid trapping soft tissues.

When milling, push firmly in the direction of the spigot axis, taking care not to tilt the mill. Mill until the cutter will no longer advance and the spigot can be seen, in the window, to have reached its end stop.

**If in doubt, continue to mill; the mill cannot continue beyond the amount permitted by the collar of the selected spigot.**

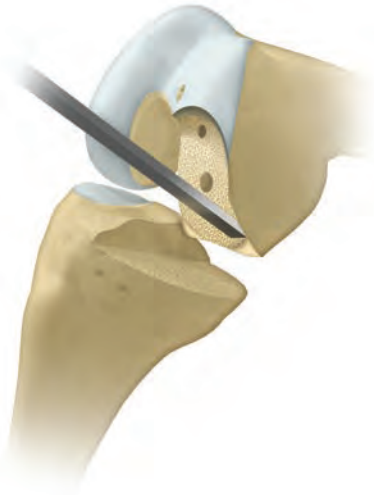

Figure 24

### First Milling of the Condyle (cont.)

Remove the mill and the spigot and trim off the bone protruding from the posterior corners of the condyle that lie outside the periphery of the cutting teeth (Figure 24). These corners should be removed tangentially to the milled surface, taking care not to damage the flat posterior surface of the condyle.

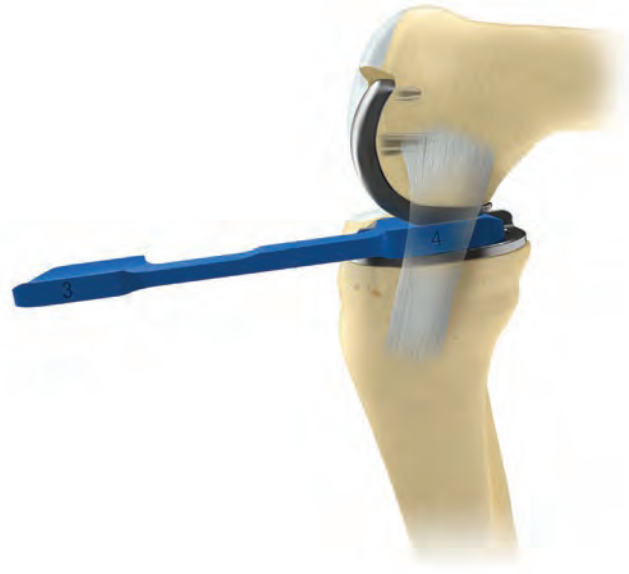

Figure 25

### Equalizing the Flexion and Extension Gaps

With the knee in 100 degrees of flexion, carefully insert the tibial template and apply the twin peg femoral trial component to the milled condyle, tapping it home with the femoral impactor angled at 45 degrees to the femoral axis.

#### Part A

With the knee in about 100 degrees of flexion carefully measure the flexion gap with the feeler gauges (Figure 25). (A previous step has already ensured that the gap is wide enough to accept at least the 4 mm gauge, 3 mm in small patients). The gauge thickness is correct when natural tension in the ligaments is achieved. Under these circumstances, the feeler gauge will easily slide in and out, but will not tilt. Confirmation of the correct size is obtained by confirming that a gauge 1 mm thicker is firmly gripped and 1 mm thinner is loose.

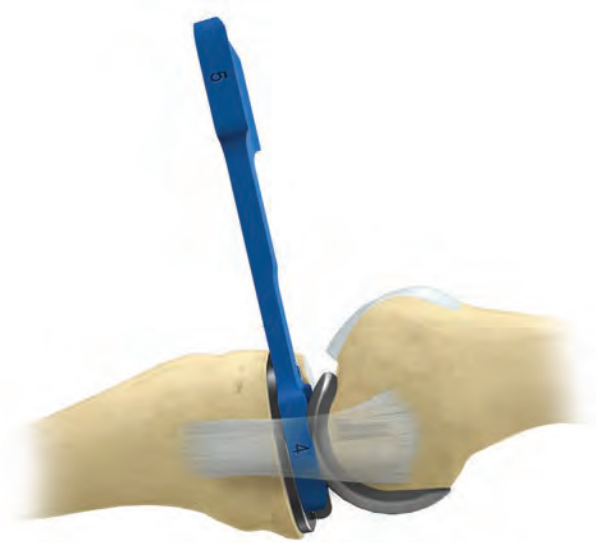

Figure 26

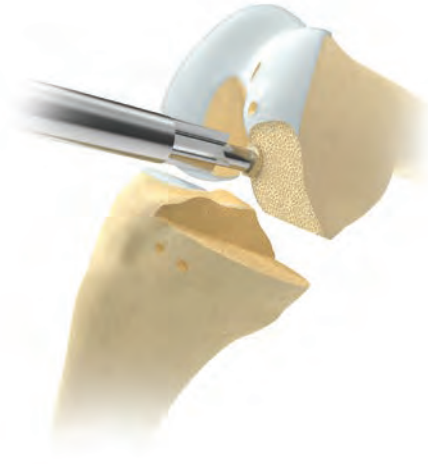

Figure 27

## Equalizing the Flexion and Extension Gaps (cont.)

### Part B

**Remove the feeler gauge.** It is important to remove the gauge before extending the knee because the extension gap is always narrower than the flexion gap at this stage. If it is left in place, the gauge may stretch or rupture the ligaments as the knee extends.

### Part C

Measure the extension gap (Figure 26) in 20 degrees of flexion, not full extension. In full extension, the posterior capsule is tight, and its influence gives a false under-measurement. The extension gap is usually less than 4 mm, if the thinnest (1 mm feeler gauge) cannot be inserted, the gap is assumed to be 0 mm.

Subtract the extension gap from the flexion gap to calculate additional bone removal. For instance, if the flexion gap measured 4 mm and the extension gap 1 mm, then the amount of bone to be milled is 3 mm. To achieve this, insert a 3 spigot and mill until the cutter will not advance further.

After each milling, it is necessary to remove the remaining bone on the posterior corners of the condyle. Also, if the circular disc of bone left under the flange of the spigot is more than 1 mm thick, it should be removed by using the bone collar remover (Figure 27). The reference for the spigot will not be lost, as its tip continues to reference off the bottom of the drill hole.

**The formula for balancing the flexion and extension gaps is as follows:**

$$\begin{aligned} \text{Flexion Gap (mm)} - \text{Extension Gap (mm)} &= \text{Thickness of bone to be milled from femur (mm)} \\ &= \text{Spigot number to be used} \end{aligned}$$

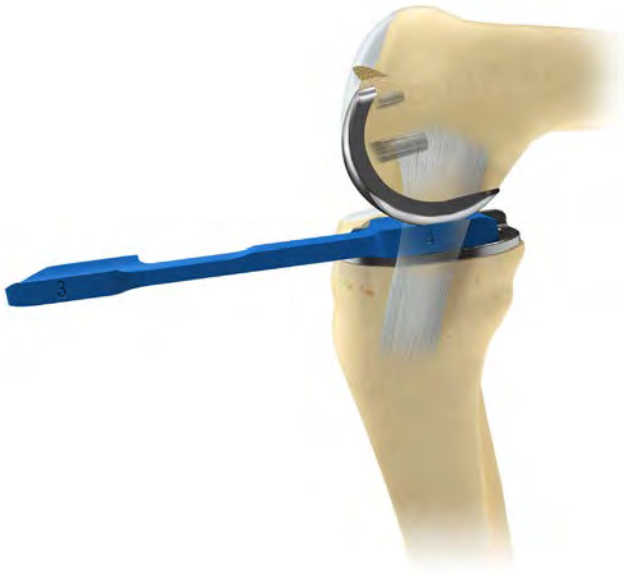

Figure 28

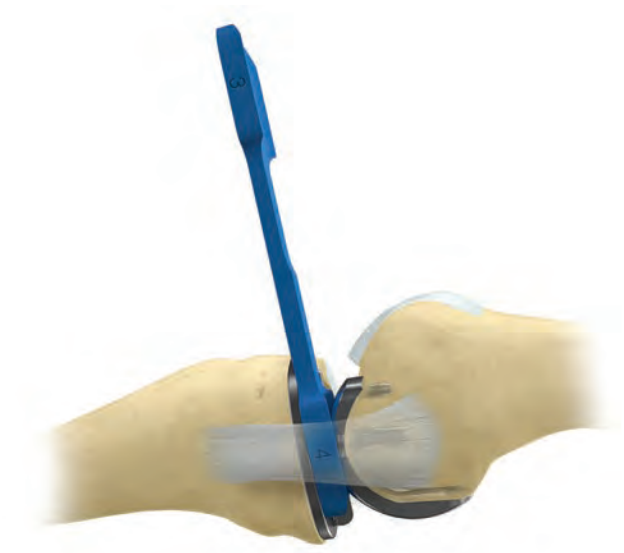

Figure 29

### Confirming Equality of the Flexion and Extension Gaps

With the tibial template and the twin peg femoral trial component in place, re-measure the flexion and extension gaps. They will usually be found to be the same (Figures 28 and 29).

If the extension gap at 20 degrees of flexion is still smaller than the flexion gap, remove more bone with the mill. This can be done, 1 mm at a time, by using the sequence of spigots. In the previous example, an additional 1 mm of bone could be removed by using a 4 spigot.

Usually the knee is balanced with a 3, 4, or 5 spigot.

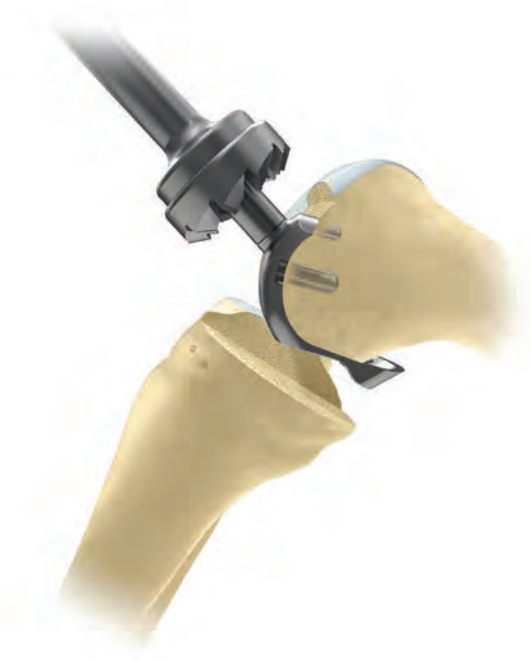

Figure 30

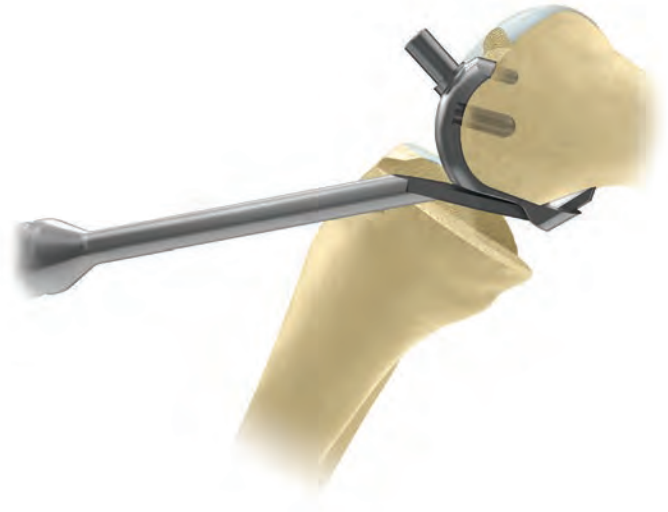


Figure 31

## Preventing Impingement

Trim the anterior and posterior condyle of the femur to reduce the risk of impingement of bone against the bearing in full extension and full flexion.

Apply the anti-impingement guide to the condyle and use the anterior mill to remove anterior bone and create clearance for the front of the bearing in full extension. When milling, push firmly in the direction of the peg axis, taking care not to tilt the mill. Mill until the cutter will not advance further (Figure 30).

Ensure that impingement does not occur between the mill and tibia by adjusting flexion.

Leave the anti-impingement guide in place and use the osteophyte chisel to remove any posterior osteophytes (Figure 31). This should be done medially and laterally as well as centrally. Remove the guide and any detached osteophytes. Palpate, with a finger, the proximal part of the condyle to ensure all osteophytes are removed.



Figure 32

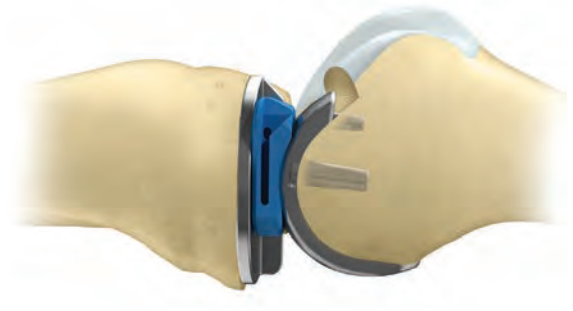


Figure 33

### Preventing Impingement (cont.)

Insert the tibial template, then the twin peg femoral trial and a trial bearing of appropriate size. With the trial components in place, manipulate the knee through full range of motion to ensure there is no impingement of bone against the bearing in full flexion and full extension (Figures 32 and 33).

Ensure the bearing is not hitting the vertical wall. If a narrow dissector put between the bearing and the wall is gripped by the bearing, consider redoing the vertical cut laterally.

Remove the trial components using the appropriate extractors.

ⓘ **Note:** Previously, feeler gauges have been used to measure the gaps because they do not stretch the ligaments. The meniscal bearings have a 3 mm high posterior lip which, after multiple insertions, may stretch the ligaments.

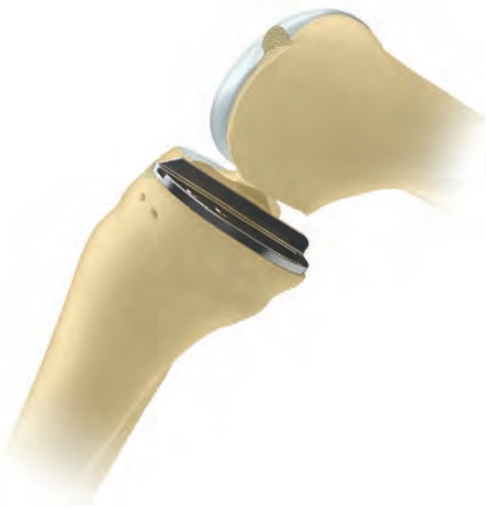

Figure 34

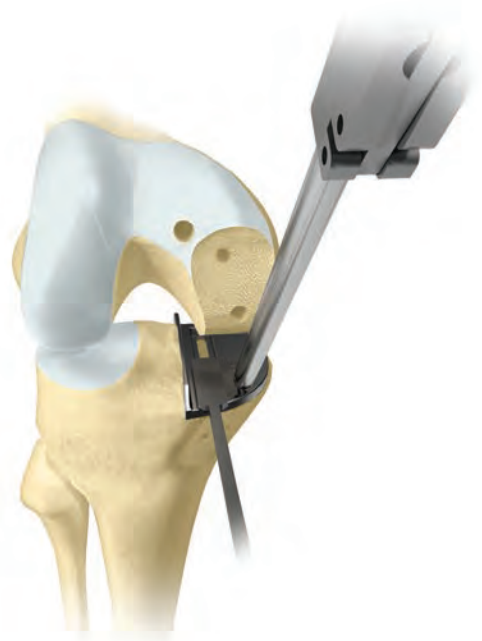

Figure 35

## Final Preparation of the Tibial Plateau

Insert the appropriate size tibial template. To ensure the correct size, position the tibial template with its posterior margin flush with the posterior tibial cortex (Figure 34). This is facilitated by passing the universal removal hook over the posterior cortex of the tibia. The tibial template should be flush with the medial cortex or overhanging slightly. If it overhangs by 2 mm or more use a smaller size tibial component.

Force the tibial plateau laterally against the vertical cut and pin in place. Hold the pin throughout sawing to prevent movement.

Introduce the keel-cut saw into the front of the slot and saw until sunk to its shoulder (Figure 35). The saw blade is lifted up and down as it is advanced posteriorly. Confirm the cut is complete by holding the pin and feeling the saw hit the front and back of the keel slot. Once the saw cuts are complete, remove the tibial template.



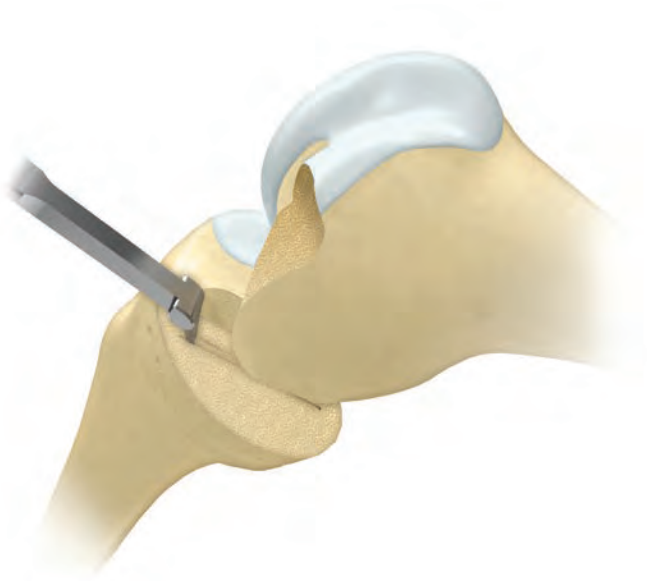


Figure 36

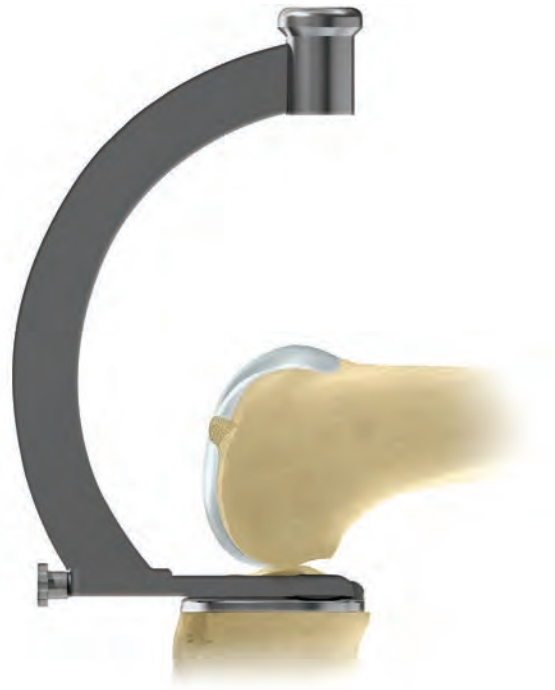

Figure 37

### Final Preparation of the Tibial Plateau (cont.)

After removing the tibial template, excavate the groove to the correct depth by scooping out the bone with the blade of the tibial gouge, taking care not to damage the anterior and posterior cortices (Figure 36).

The safest way to prepare the back of the groove is to feel the posterior cortex with the tibial keel pick and then move it anteriorly by 5 mm before pushing down and bringing forward to empty the groove.

Insert the trial tibial component and tap with the tibial impactor until fully seated (Figure 37).

Ensure component is flush with the bone and the posterior margin extends to the back of the tibia. If the component does not seat fully remove it and clean the keel slot out again with the tibial gouge.

Use only the toffee hammer to avoid the risk of plateau fracture.

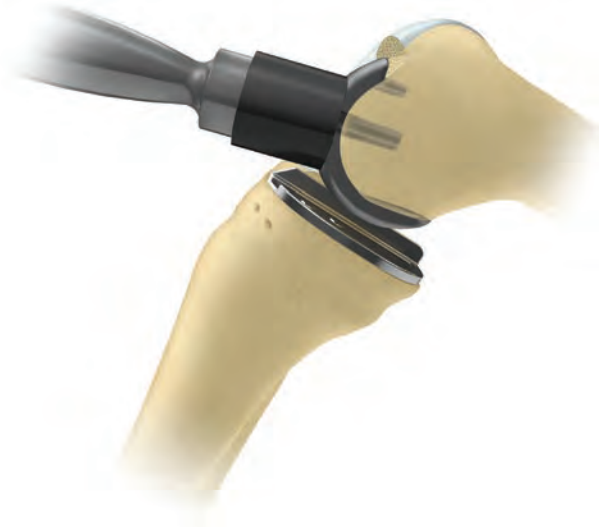

Figure 38

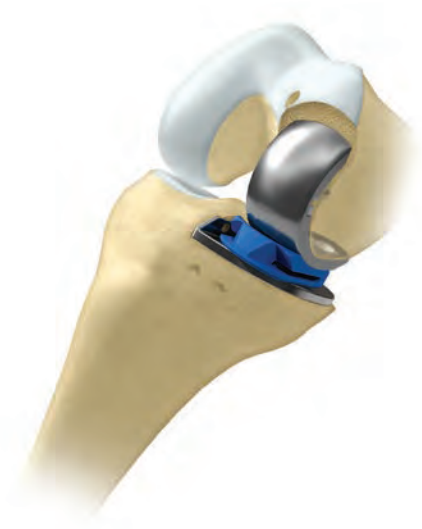

Figure 39

### Final Trial Reduction

Insert the femoral trial component and ensure it is fully seated by tapping home with the femoral impactor at 45 degrees to the femoral axis (Figure 38).

Insert a trial meniscal bearing of the chosen thickness (Figure 39).

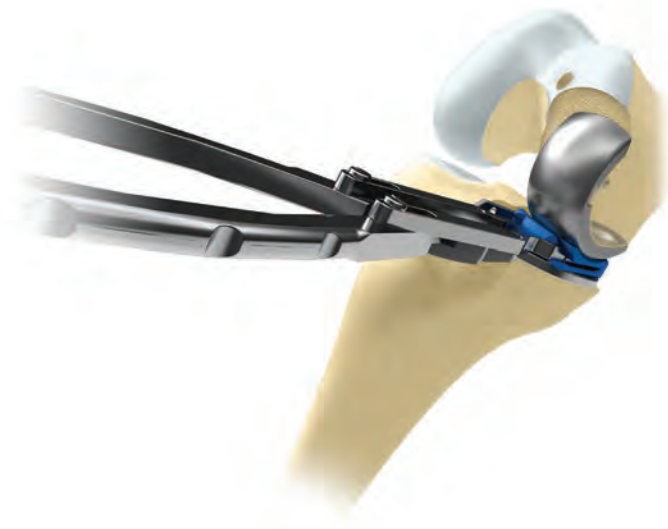


Figure 40

### Final Trial Reduction (cont.)

With the bearing in place, manipulate the knee through a full range of motion to demonstrate stability of the joint, security of the bearing and absence of impingement. The thickness of the bearing should be such as to restore the ligaments to their natural tension so that, when a valgus force is applied to the knee, the artificial joint surfaces distract a millimeter or two.

This test should be done with the knee in 20 degrees of flexion. In full extension, the bearing will be firmly gripped because of the tight posterior capsule.

Remove the bearing with the bearing extractor (Figure 40).

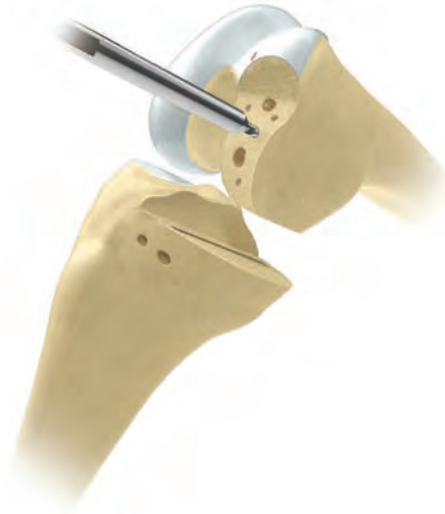

Figure 41

## Cementing the Components

Roughen the femoral and tibial surfaces including the posterior condyles, by making multiple small drill holes with the cement key drill (Figure 41).

The components are fixed with two separate mixes of cement.

### The Tibial Component

Place a small amount of cement on the tibial bone surface and flatten to produce a thin layer covering the whole under surface. Insert the component and press down, first posteriorly and then anteriorly, to squeeze out excess cement at the front.

Use the right-angled tibial impactor with a small mallet to complete the insertion. Ensure there is no soft tissue under the component. Remove excess cement with a Woodson cement curette from the margins of the component. Insert the twin peg femoral trial component and pressurize cement by inserting the appropriate feeler gauge. With the feeler gauge inserted, hold the leg in 45 degrees of flexion while the cement sets. Do not fully extend or flex the leg, as this may rock the component.

Once the cement has set, remove the feeler gauge and twin peg femoral trial component and look carefully for cement that may have extruded. Slide the flat plastic probe along the tibial articular surface, feeling for cement at the edges and posteriorly.

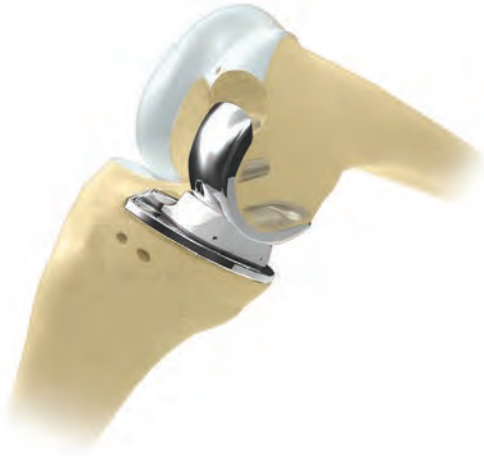

Figure 42

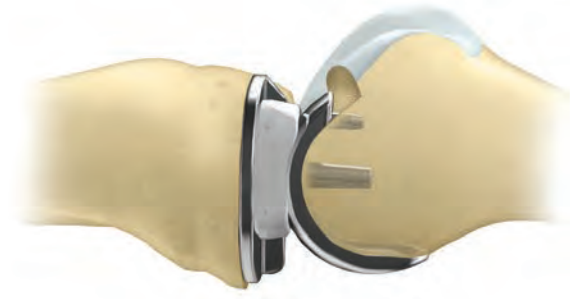


Figure 43

### The Femoral Component

From the second mix, force cement into the large femoral drill hole and fill the concave surface of the femoral component with cement. Apply the loaded component to the condyle and impact with the punch held at 45 degrees to the long axis of the femur. Remove excess cement from the margins with a Woodson cement curette. Pressurize the cement by inserting the appropriate feeler gauge with the knee at 45 degrees of flexion and holding the leg in this position. Do not fully extend or flex the knee or this may rock the components and may loosen them.

Once the cement has set, remove the feeler gauge. Clear the medial and lateral margins of the component of any extruded cement. The posterior margin cannot be seen but can be palpated with a curved dissector.

Reassess the gap by inserting a trial bearing. Occasionally a smaller size is needed due to gap closure from the cement mantle.

Complete the reconstruction by snapping the chosen bearing into place (Figures 42 and 43).

Close the wound in a routine manner.

## Appendix

### Postoperative Treatment

Forcing flexion of the knee during the first postoperative week often causes pain and is unnecessary since movements are almost always recovered spontaneously.

### Postoperative Radiographic Assessment

Postoperative radiographs can be used to measure the technical success of the operation. For this purpose, as well as to facilitate their comparison with follow-up radiographs, the films should be taken in a reproducible manner. Even small variations in the angle of incidence of the X-ray beam can distort the images of the components and make accurate assessment of their positions and bone/cement interfaces difficult.<sup>6</sup>

### Radiographic Technique

Accurately aligned radiographs are best taken with an image intensifier (fluoroscope). If this is not available, a digital system can be used. Low dose images are taken and then adjusted until the optimal image is obtained.

#### Anterior Projection

The shape of the tibial component allows it to be used to center the X-ray beam and to align it in all three planes. Position the patient supine on a standard fluoroscopic screening table with an undercouch tube and an image intensifier. Before taking the film, adjust the position of the limb by flexing/extending the knee and internally/externally rotating the leg until the tibial component appears on the screen directly 'end-on.'

#### Lateral Projection

With the leg flexed 40 degrees, internally/externally rotate the thigh until the tibial component appears on the screen directly 'edge-on.'

The components ideally implanted are shown (Figure 44).

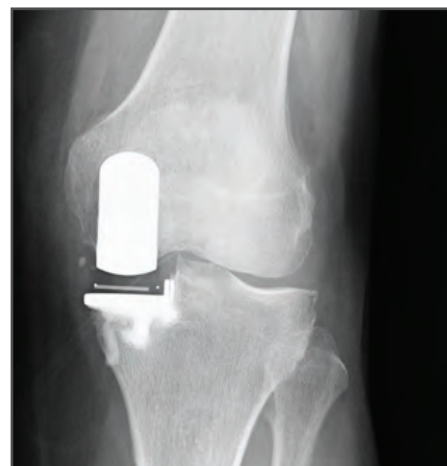
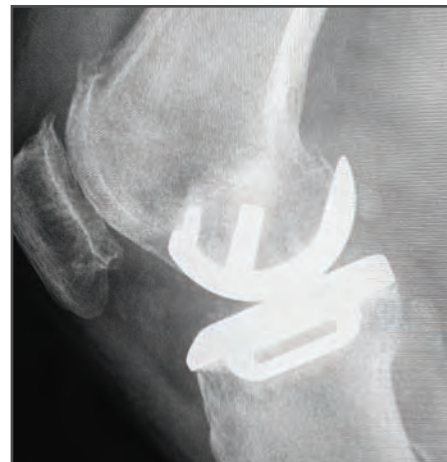
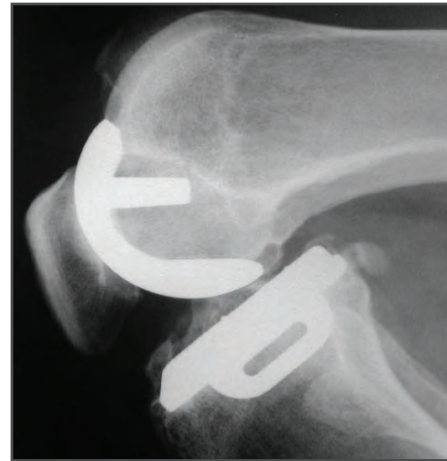Figure 44

## Radiographic Criteria

If all steps have been followed as described in this surgical technique, the postoperative appearances should be as shown (Figure 45).

## Position and Size of Components

### Femoral Component (Relative to the Femur)

|     |                          |  |
|-----|--------------------------|--|
| A/A | Varus/valgus angle       | < 10 degrees varus — < 10 degrees valgus   |
| B/B | Flexion/extension angle  | 15 degrees flexion — < 0 degrees extension |
| C/C | Medial/lateral placement | Central                                    |
| D   | Posterior fit            | Flush or < 4 mm overhang                   |

### Tibial Component (Relative to the Tibia)

|     |                      |  |
|-----|----------------------|--|
| E/E | Varus/valgus angle   | < 5 degrees varus — < 5 degrees valgus |
| F/F | Posteroinferior tilt | 7 degrees + or - 5 degrees             |
| G   | Medial fit           | Flush or < 2 mm overhang               |
| H   | Posterior fit        | Flush or < 2 mm overhang               |
| J   | Anterior fit         | Flush or < 5 mm short                  |
| K   | Lateral fit          | Flush — No gap                         |

### Meniscal Bearing

#### (Relative to the Tibial Component)

|   |   |
|---|---|
| L | X-ray marker central and parallel with the tibial component |
|---|---|

### Bone Interfaces

|   |                   |                              |
|---|-------------------|------------------------------|
| M | Posterior femoral | Parallel surfaces: Cement OK |
| N | Tibial            | Parallel surfaces: Cement OK |

### Other

|   |                          |                                  |
|---|--------------------------|----------------------------------|
| O | Posterior osteophytes    | None visible                     |
| P | Depth of tibial saw cuts | Minimal ingress of cement        |
| Q | Intact posterior cortex  | No extruded cement posteriorly   |
| R | No anterior impingement  | Adequate bone removed; no cement |

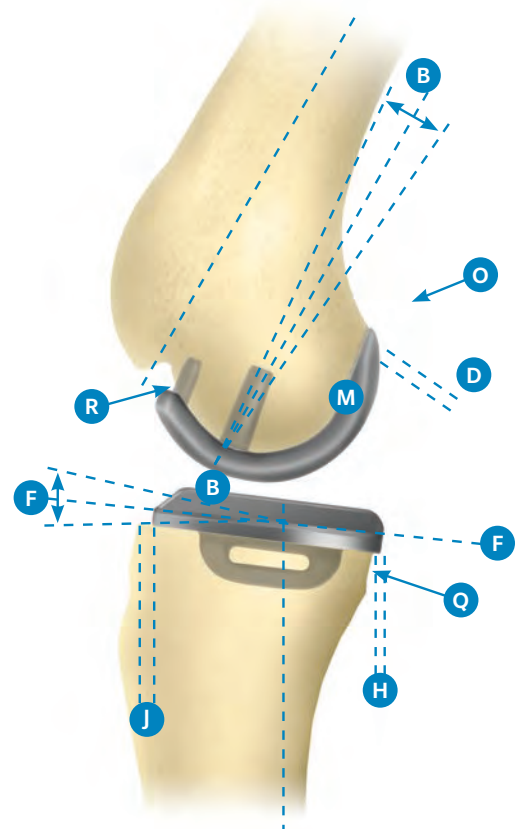
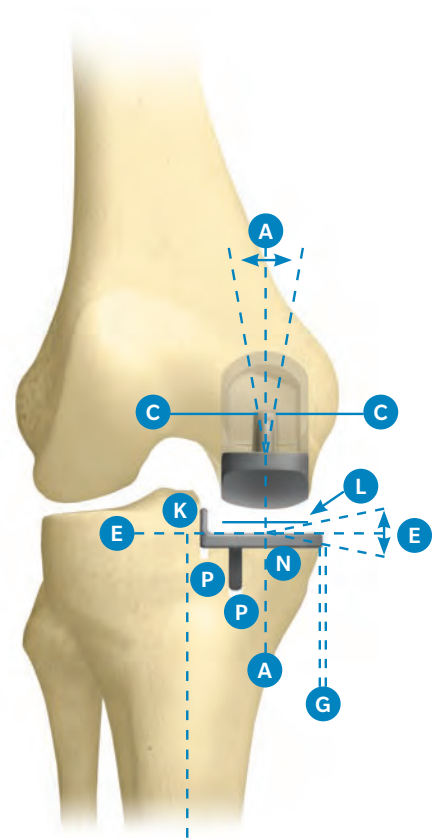


Figure 45

## Follow-up Radiographs

All subsequent radiographs should be taken in the same manner as the immediate postoperative films to allow comparison. Fluoroscopically centered films are particularly appropriate for demonstrating the state of the interface beneath the tibial plateau.

This interface changes gradually during the first year after implantation, after which it should remain unaltered. The typical appearance at one year and ten years is a thin radiolucent line (approximately 1 mm). Histologically, the radiolucent line represents a layer of fibrocartilage, with its collagen organized parallel with the plateau. The radiodense line represents a new 'subchondral bone plate.' The trabeculae, which were cut at the operation, attach to this plate and support it.<sup>17</sup> The collagen fibers of the cartilage layer insert into its upper surface. There are some areas within the radiolucency in which there is direct contact between cement and bone.

The appearances under the femoral component are the same, but are not easily demonstrated because of the non-planar form of the femoral interface.


The radiographic changes which occur during the first postoperative year result from healing of the cut bone and its remodeling to sustain the new pattern of compressive load applied to it by the rigid implant.

A review of Oxford Partial Knee patients found no relationship between the presence of radiolucent lines and clinical outcomes.<sup>20</sup> Therefore, it is important not to ascribe clinical symptoms to these 'normal' appearances or to interpret them as evidence of implant loosening, i.e. radiolucent line.




## Implants


### Femoral Components

| Product   | Part Number | Description                       | Size    |
|---|-------------|-----------------------------------|---------|
|  | 161467      | Oxford Twin Peg Femoral Component | X-small |
|   | 161468      | Oxford Twin Peg Femoral Component | Small   |
|   | 161469      | Oxford Twin Peg Femoral Component | Medium  |
|   | 161470      | Oxford Twin Peg Femoral Component | Large   |
|   | 161471      | Oxford Twin Peg Femoral Component | X-large |


### Tibial Components

| Product   | Part Number | Description                           | Size |
|---|-------------|---------------------------------------|------|
|  | 159531      | Oxford Tibial Component, Left Medial  | AA   |
|   | 159532      | Oxford Tibial Component, Right Medial | AA   |
|   | 154718      | Oxford Tibial Component, Left Medial  | A    |
|   | 154719      | Oxford Tibial Component, Right Medial | A    |
|   | 154720      | Oxford Tibial Component, Left Medial  | B    |
|   | 154721      | Oxford Tibial Component, Right Medial | B    |
|   | 154722      | Oxford Tibial Component, Left Medial  | C    |
|   | 154723      | Oxford Tibial Component, Right Medial | C    |
|   | 154724      | Oxford Tibial Component, Left Medial  | D    |
|   | 154725      | Oxford Tibial Component, Right Medial | D    |
|   | 154726      | Oxford Tibial Component, Left Medial  | E    |
|   | 154727      | Oxford Tibial Component, Right Medial | E    |
|   | 154775      | Oxford Tibial Component, Left Medial  | F    |
|   | 154776      | Oxford Tibial Component, Right Medial | F    |





### Tibial Bearings





| Product   | Part Number |        |        |        |         | Description |       |
|---|-------------|--------|--------|--------|---------|-------------|-------|
|   | X-small     | Small  | Medium | Large  | X-large | Thickness   | Side  |
|  | 159790      | 159540 | 159547 | 159554 | 159561  | 3 mm        | Left  |
|   | 159791      | 159541 | 159548 | 159555 | 159562  | 4 mm        |       |
|   | 159792      | 159542 | 159549 | 159556 | 159563  | 5 mm        |       |
|   | 159793      | 159543 | 159550 | 159557 | 159564  | 6 mm        |       |
|   | 159794      | 159544 | 159551 | 159558 | 159565  | 7 mm        |       |
|   | 159795      | 159545 | 159552 | 159559 | 159566  | 8 mm        |       |
|   | 159796      | 159546 | 159553 | 159560 | 159567  | 9 mm        |       |
|   | 160790      | 159568 | 159575 | 159582 | 159589  | 3 mm        | Right |
|   | 160791      | 159569 | 159576 | 159583 | 159590  | 4 mm        |       |
|   | 160792      | 159570 | 159577 | 159584 | 159591  | 5 mm        |       |
|   | 160793      | 159571 | 159578 | 159585 | 159592  | 6 mm        |       |
|   | 160794      | 159572 | 159579 | 159586 | 159593  | 7 mm        |       |
|   | 160795      | 159573 | 159580 | 159587 | 159594  | 8 mm        |       |
|   | 160796      | 159574 | 159581 | 159588 | 159595  | 9 mm        |       |


## Instrumentation









### 32-423539 Tibial Case 1—Upper Insert Tray




| Product   | Label     | Part Number                         | Description                                    | Size |
|---|-----------|-------------------------------------|--|------|
|   |           | 32-423539                           | Oxford Microplasty Instrument Tray (Tray Only) | –    |
|  | A         | 32-421066                           | Oxford Tibial Template Left Medial             | AA   |
|   |           | 32-421067                           | Oxford Tibial Template Right Medial            | AA   |
|   | 32-420825 | Oxford Tibial Template Left Medial  | A  |      |
|   | 32-420826 | Oxford Tibial Template Right Medial | A  |      |
|   | 32-420056 | Oxford Tibial Template Right Medial | B  |      |
|   | 32-420057 | Oxford Tibial Template Left Medial  | B  |      |
|   | 32-420058 | Oxford Tibial Template Right Medial | C  |      |
|   | 32-420059 | Oxford Tibial Template Left Medial  | C  |      |
|   | 32-420060 | Oxford Tibial Template Right Medial | D  |      |
|   | 32-420061 | Oxford Tibial Template Left Medial  | D  |      |
|   | 32-420062 | Oxford Tibial Template Right Medial | E  |      |
|   | 32-420063 | Oxford Tibial Template Left Medial  | E  |      |
|   | 32-420827 | Oxford Tibial Template Left Medial  | F  |      |
|   | 32-420828 | Oxford Tibial Template Right Medial | F  |      |
|  | B         | 32-467619                           | Quick-Release Drill Bit (PK/2)                 | –    |
|  | C         | 32-420802                           | Tibial Resection Headless Pin (PK/2)           | –    |
|  | D         | 32-347911                           | Bone Pin (PK/2)                                | –    |

| Product   | Label | Part Number | Description                      | Size |
|---|-------|-------------|----------------------------------|------|
|    | E     | 32-420160   | Pin Inserter/Extractor           | –    |
|    | F     | 32-422455   | Oxford Tibial Template Nail      | –    |
|    | G     | 32-421064   | Oxford Tibial Trial Left Medial  | AA   |
|   |       | 32-421065   | Oxford Tibial Trial Right Medial | AA   |
|   |       | 32-420820   | Oxford Tibial Trial Left Medial  | A    |
|   |       | 32-420821   | Oxford Tibial Trial Right Medial | A    |
|   |       | 32-420730   | Oxford Tibial Trial Left Medial  | B    |
|   |       | 32-420731   | Oxford Tibial Trial Right Medial | B    |
|   |       | 32-420732   | Oxford Tibial Trial Left Medial  | C    |
|   |       | 32-420733   | Oxford Tibial Trial Right Medial | C    |
|   |       | 32-420734   | Oxford Tibial Trial Left Medial  | D    |
|   |       | 32-420735   | Oxford Tibial Trial Right Medial | D    |
|   |       | 32-420736   | Oxford Tibial Trial Left Medial  | E    |
|   |       | 32-420737   | Oxford Tibial Trial Right Medial | E    |
|   |       | 32-420822   | Oxford Tibial Trial Left Medial  | F    |
|   |       | 32-420823   | Oxford Tibial Trial Right Medial | F    |
|  | H     | 32-467618   | AGC® Quick Release Drill Chuck   | –    |




### 32-423539 Tibial Case 1—Lower Insert Tray





| Product   | Label | Part Number | Description                                    | Size |
|---|-------|-------------|--|------|
|  |       | 32-423539   | Oxford Microplasty Instrument Tray (Tray Only) | –    |
|  | A     | 32-422365   | Oxford Slap hammer                             | –    |
|  | B     | 32-422991   | Woodson Cement Curette                         | –    |
|  | C     | 32-420932   | Oxford Tibial Impactor                         | –    |
|  | D     | 32-420804   | Oxford Cement Removal Chisel                   | –    |
|  | E     | 32-401111   | Oxford IM Rod Removal Hook                     | –    |



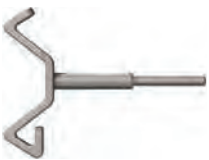


| Product   | Label | Part Number | Description                                    | Size |
|---|-------|-------------|--|------|
|  | F     | 32-422718   | Oxford Trial Tibial Bearing Inserter/Extractor | -    |
|  | G     | 32-420660   | Oxford Hex Driver                              | -    |
|  | H     | 32-422936   | Oxford Tibial Groove Cutter (Cemented)         | -    |






### 32-423540 Tibial Case 2—Upper Insert Tray

| Product   | Label | Part Number  | Description  | Size   |
|---|-------|--|--|--|
|   |       | 32-423540  | Oxford Microplasty Instrument Tray (Tray Only)   | –  |
|  | A     | 3000-02  | MCL Retractor  | –  |
|  | B     | 32-422985<br>32-423223<br>32-422987<br>32-423230<br>32-423231<br>32-422990<br>32-423222<br>32-422988 | Oxford Tibial Shim, Right Medial<br>Oxford Slotted Tibial Shim, Right Medial<br>Oxford Tibial Shim, Right Medial<br>Oxford Slotted Tibial Shim, Right Medial<br>Oxford Slotted Tibial Shim, Left Medial<br>Oxford Tibial Shim, Left Medial<br>Oxford Slotted Tibial Shim, Left Medial<br>Oxford Tibial Shim, Left Medial | 0 mm<br>0 mm<br>2 mm<br>2 mm<br>2 mm<br>2 mm<br>0 mm<br>0 mm |
|  | C     | 32-423200  | Oxford Microplasty Tibial Resector Body Tube   | –  |
|  | D     | 32-422778  | Oxford Silicone Ankle Strap  | –  |











| Product   | Label | Part Number   | Description                    | Size   |
|---|-------|---|--------------------------------|--|
|    | E     | 32-422828<br>32-422792<br>32-422795<br>32-422798<br>32-422839<br>32-423285<br>32-423286 | Oxford Tibial Gap Sizing Spoon | 1 mm<br>1 mm<br>1 mm<br>1 mm<br>1 mm<br>2 mm<br>3 mm |
|    | F     | 32-422848   | Oxford IM Rod Pusher           | -  |
|    | G     | 32-422777   | Ankle Yoke                     | -  |
|   | H     | 32-422822   | Oxford IM Link                 | -  |
|  | I     | 32-422846<br>32-422863  | Oxford Tibial Resector Stylus  | 3 mm<br>4 mm   |




### 32-423540 Tibial Case 2—Lower Insert Tray

| Product | Label | Part Number | Description                                    | Size   |
|---------|-------|-------------|--|--------|
|         |       | 32-423540   | Oxford Microplasty Instrument Tray (Tray Only) | –      |
|         | A     | 32-423232   | Oxford Anterior Bone Removal Shaft (Outer)     | –      |
|         | B     | 32-422984   | Cannulated IM rod                              | 300 mm |
|         | C     | 32-422847   | Cannulated IM rod                              | 200 mm |
|         | D     | 32-420127   | Femoral Impactor                               | –      |
|         | E     | 32-423233   | Oxford Anterior Bone Removal Shaft (Inner)     | –      |
|         | F     | 32-423226   | Concise Oxford IM Awl                          | 5 mm   |
|         | G     | 32-422760   | Toffee Hammer                                  | –      |














| Product   | Label | Part Number  | Description   | Size                                 |
|---|-------|--|---|--------------------------------------|
|    | H     | 32-423287  | Bone Collar Remover   | –                                    |
|    | I     | 32-420333<br>32-420334<br>32-420335<br>32-420336<br>32-420337<br>32-420338<br>32-420339<br>32-420340 | Oxford Spigot   | 7<br>6<br>5<br>4<br>3<br>2<br>1<br>0 |
|    | J     | 32-420663<br>32-420664<br>32-420665  | Oxford Metal Shim   | 1 mm<br>2 mm<br>3 mm                 |
|    | K     | 32-423227  | Oxford Cement Key Drill   | –                                    |
|  | L     | 32-423228  | Oxford Quick Release Femoral Drill Bit  | 4 mm                                 |
|  | M     | 32-422845  | Oxford Quick Release Femoral Drill Bit  | 6.35 mm                              |
|  | N     | 42-411400  | Signature™ Alignment Rod*   | –                                    |
|  | O     | 42-411402<br>42-411403   | Oxford Signature Tibial Alignment Checker Left*<br>Oxford Signature Tibial Alignment Checker Right* | –                                    |
|  | P     | 42-411420  | Oxford Signature Tibial Drill Guide*  | –                                    |
|  | Q     | 42-411401  | Oxford Signature Femoral Alignment Checker*   | –                                    |

\* Not photographed, not a part of standard set definition

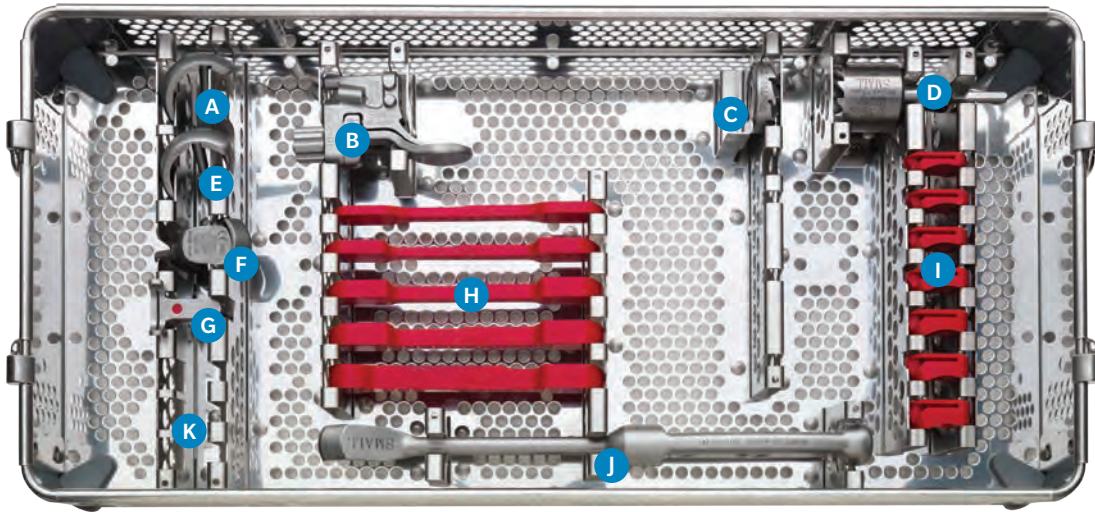


### 32-423527 Femoral Instruments — X-small






| Product   | Label | Part Number | Description                                    | Size    |
|---|-------|-------------|--|---------|
|   |       | 32-423534   | Oxford Microplasty Instrument Tray (Tray Only) | –       |
|  | A     | 32-421050   | Oxford Single Peg Femoral Trial                | X-small |
|  | B     | 32-422974   | Oxford Femoral Drill Guide                     | X-small |
|  | C     | 32-423234   | Oxford Anterior Bone Mill                      | X-small |
|  | D     | 32-421062   | Oxford Spherical Mill                          | X-small |
|  | E     | 32-422952   | Oxford Twin Peg Femoral Trial                  | X-small |







| Product   | Label | Part Number   | Description                      | Size                                 |
|---|-------|---|----------------------------------|--------------------------------------|
|    | F     | 32-423235   | Oxford Anti-impingement Guide    | X-small                              |
|    | G     | 32-422979   | Oxford Posterior Resection Guide | X-small                              |
|    | H     | 32-422766<br>32-422767<br>32-422768<br>32-422769              | Oxford Gap Gauge, X-small        | 1/2 mm<br>3/4 mm<br>5/6 mm<br>7/8 mm |
|    | I     | 32-422693<br>32-422694<br>32-422695<br>32-422696<br>32-422697 | Oxford Trial Bearing, X-small    | 3 mm<br>4 mm<br>5 mm<br>6 mm<br>7 mm |
|   | J     | 32-422938   | Oxford Chisel                    | X-small                              |
|  | K     | 42-411430<br>42-411431  | Oxford Signature Drill Guides*   | X-small<br>Small                     |

\* Not photographed, not a part of standard set definition




### 32-423528 Femoral Instruments — Small






| Product   | Label | Part Number | Description                                    | Size  |
|---|-------|-------------|--|-------|
|   |       | 32-423535   | Oxford Microplasty Instrument Tray (Tray Only) | –     |
|  | A     | 32-420341   | Oxford Single Peg Femoral Trial                | Small |
|  | B     | 32-422975   | Oxford Femoral Drill Guide                     | Small |
|  | C     | 32-423236   | Oxford Anterior Bone Mill                      | Small |
|  | D     | 32-420329   | Oxford Spherical Mill                          | Small |
|  | E     | 32-422953   | Oxford Twin Peg Femoral Trial                  | Small |

| Product   | Label | Part Number   | Description                      | Size   |
|---|-------|---|----------------------------------|--|
|    | F     | 32-423237   | Oxford Anti-impingement Guide    | Small  |
|    | G     | 32-422980   | Oxford Posterior Resection Guide | Small  |
|    | H     | 32-422771<br>32-422801<br>32-422802<br>32-422803<br>32-422804                           | Oxford Gap Gauge, Small          | 1/2 mm<br>3/4 mm<br>5/6 mm<br>7/8 mm<br>9 mm         |
|    | I     | 32-422698<br>32-422699<br>32-422700<br>32-422701<br>32-422702<br>32-422721<br>32-422722 | Oxford Trial Bearing, Small      | 3 mm<br>4 mm<br>5 mm<br>6 mm<br>7 mm<br>8 mm<br>9 mm |
|  | J     | 32-422937   | Oxford Chisel                    | Small  |
|  | K     | 42-411434<br>42-411435<br>42-411436   | Oxford Signature Drill Guides*   | Small Downsize<br>Small<br>Small Upsize              |







\* Not photographed, not a part of standard set definition



### 32-423529 Femoral Instruments — Medium


| Product   | Label | Part Number | Description                                    | Size   |
|---|-------|-------------|--|--------|
|   |       | 32-423536   | Oxford Microplasty Instrument Tray (Tray Only) | –      |
|  | A     | 32-420342   | Oxford Single Peg Femoral Trial                | Medium |
|  | B     | 32-422976   | Oxford Femoral Drill Guide                     | Medium |
|  | C     | 32-423238   | Oxford Anterior Bone Mill                      | Medium |
|  | D     | 32-420330   | Oxford Spherical Mill                          | Medium |
|  | E     | 32-422954   | Oxford Twin Peg Femoral Trial                  | Medium |








| Product   | Label | Part Number   | Description                      | Size   |
|---|-------|---|----------------------------------|--|
|    | F     | 32-423239   | Oxford Anti-impingement Guide    | Medium   |
|    | G     | 32-422981   | Oxford Posterior Resection Guide | Medium   |
|    | H     | 32-422805<br>32-422806<br>32-422807<br>32-422808<br>32-422809                           | Oxford Gap Gauge, Medium         | 1/2 mm<br>3/4 mm<br>5/6 mm<br>7/8 mm<br>9 mm         |
|    | I     | 32-422703<br>32-422704<br>32-422705<br>32-422706<br>32-422707<br>32-422723<br>32-422724 | Oxford Trial Bearing, Medium     | 3 mm<br>4 mm<br>5 mm<br>6 mm<br>7 mm<br>8 mm<br>9 mm |
|  | J     | 32-422344   | Oxford Chisel                    | Medium   |
|  | K     | 42-411439<br>42-411440<br>42-411441   | Oxford Signature Drill Guides*   | Medium Downsize<br>Medium<br>Medium Upsize           |







\* Not photographed, not a part of standard set definition






### 32-423530 Femoral Instruments — Large






| Product   | Label | Part Number | Description                                    | Size  |
|---|-------|-------------|--|-------|
|   |       | 32-423537   | Oxford Microplasty Instrument Tray (Tray Only) | –     |
|  | A     | 32-420343   | Oxford Single Peg Femoral Trial                | Large |
|  | B     | 32-422977   | Oxford Femoral Drill Guide                     | Large |
|  | C     | 32-423240   | Oxford Anterior Bone Mill                      | Large |
|  | D     | 32-420331   | Oxford Spherical Mill                          | Large |
|  | E     | 32-422955   | Oxford Twin Peg Femoral Trial                  | Large |







| Product   | Label | Part Number   | Description                      | Size   |
|---|-------|---|----------------------------------|--|
|    | F     | 32-423241   | Oxford Anti-impingement Guide    | Large  |
|    | G     | 32-422982   | Oxford Posterior Resection Guide | Large  |
|    | H     | 32-422810<br>32-422811<br>32-422812<br>32-422813<br>32-422814                           | Oxford Gap Gauge, Large          | 1/2 mm<br>3/4 mm<br>5/6 mm<br>7/8 mm<br>9 mm         |
|    | I     | 32-422708<br>32-422709<br>32-422710<br>32-422711<br>32-422712<br>32-422725<br>32-422726 | Oxford Trial Bearing, Large      | 3 mm<br>4 mm<br>5 mm<br>6 mm<br>7 mm<br>8 mm<br>9 mm |
|  | J     | 32-422935   | Oxford Chisel                    | Large  |
|  | K     | 42-411444<br>42-411445<br>42-411446   | Oxford Signature Drill Guides*   | Large Downsize<br>Large<br>Large Upsize              |

\* Not photographed, not a part of standard set definition



### 32-423531 Femoral Instruments — X-large

| Product   | Label | Part Number | Description                                    | Size    |
|---|-------|-------------|--|---------|
|   |       | 32-423538   | Oxford Microplasty Instrument Tray (Tray Only) | –       |
|  | A     | 32-420344   | Oxford Single Peg Femoral Trial                | X-large |
|  | B     | 32-422978   | Oxford Femoral Drill Guide                     | X-large |
|  | C     | 32-423242   | Oxford Anterior Bone Mill                      | X-large |
|  | D     | 32-420332   | Oxford Spherical Mill                          | X-large |
|  | E     | 32-422956   | Oxford Twin Peg Femoral Trial                  | X-large |

| Product   | Label | Part Number   | Description                      | Size   |
|---|-------|---|----------------------------------|--|
|    | F     | 32-423243   | Oxford Anti-impingement Guide    | X-large  |
|    | G     | 32-422983   | Oxford Posterior Resection Guide | X-large  |
|    | H     | 32-422815<br>32-422816<br>32-422817<br>32-422818<br>32-422819                           | Oxford Gap Gauge, X-large        | 1/2 mm<br>3/4 mm<br>5/6 mm<br>7/8 mm<br>9 mm         |
|    | I     | 32-422713<br>32-422714<br>32-422715<br>32-422716<br>32-422717<br>32-422727<br>32-422728 | Oxford Trial Bearing, X-large    | 3 mm<br>4 mm<br>5 mm<br>6 mm<br>7 mm<br>8 mm<br>9 mm |
|  | J     | 32-422939   | Oxford Chisel                    | X-large  |
|  | K     | 42-411449<br>42-411450  | Oxford Signature Drill Guides*   | X-large Downsize<br>X-large                          |

\* Not photographed, not a part of standard set definition

Biomet UK Ltd.  
Waterton Industrial Estate  
Bridgend CF31 3XA, UK

Ref: 5401000201  
Revision: L  
Date: June 2015

## OXFORD® PARTIAL KNEE SYSTEM

### ATTENTION OPERATING SURGEON

#### DESCRIPTION

The Oxford Partial Knee is a medial partial knee replacement system consisting of a femoral component, a tibial component and a freely mobile meniscal bearing.

#### Materials

|                    |   |
|--------------------|---|
| Femoral Component: | CoCrMo Alloy                                      |
| Tibial Component:  | CoCrMo Alloy                                      |
| Meniscal Bearing:  | Ultra-High Molecular Weight Polyethylene (UHMWPE) |
| Marker Wire:       | Titanium Alloy                                    |
| Marker Balls:      | Tantalum  |

#### INDICATIONS

The Oxford Partial Knee is intended for use in individuals with osteoarthritis or avascular necrosis limited to the medial compartment of the knee and is intended to be implanted with bone cement.

#### CONTRAINDICATIONS

Contraindications include:

1. Infection, sepsis, and osteomyelitis.
2. Use in the lateral compartment of the knee.
3. Rheumatoid arthritis or other forms of inflammatory joint disease.
4. Revision of a failed prosthesis, failed upper tibial osteotomy or post-traumatic arthritis after tibial plateau fracture.
5. Insufficiency of the collateral, anterior or posterior cruciate ligaments which would preclude stability of the device.
6. Full thickness damage to the weight bearing area of the lateral compartment of the knee.
7. Uncooperative patient or patient with neurologic disorders who are incapable of following directions.
8. Insufficient bone stock to provide adequate support and/or fixation to the prosthesis.
9. Metabolic disorders which may impair bone formation.
10. Osteomalacia.
11. Distant foci of infections which may spread to the implant site.
12. Rapid joint destruction, marked bone loss or bone resorption apparent on roentgenogram.
13. Vascular insufficiency, muscular atrophy, neuromuscular disease.
14. Incomplete or deficient soft tissue surrounding the knee.
15. Charcot's disease.
16. A fixed varus deformity (not passively correctable) of greater than 15 degrees.
17. A fixed flexion deformity (not passively correctable) of greater than 15 degrees.

#### WARNINGS

1. Improper selection, placement, positioning, alignment and fixation of the implant components may result in unusual stress conditions which may lead to subsequent reduction in the service life of the prosthetic components.
2. Improper preoperative or intraoperative implant handling or damage (scratches, dents, etc.) can lead to crevice corrosion, fretting, fatigue fracture and/or excessive wear.
3. Do not modify implants.
4. Do not reuse implants. While an implant may appear undamaged, previous stress may have created imperfections that would reduce the service life of the implant. Do not treat patients with implants that have been, even momentarily, placed in a different patient. Furthermore, re-using an implant could cause patient contamination.
5. Malalignment or soft tissue imbalance can place inordinate forces on the components which may cause excessive wear to the patellar or tibial bearing articulating surfaces. Revision surgery may be required to prevent component failure.
6. Care is to be taken to ensure complete support of all parts of the device embedded in bone cement to reduce risk of stress concentrations, which may lead to failure of the procedure. Complete pre-closure cleaning and removal of bone cement debris, metallic debris, and other surgical debris at the implant site is critical to minimize wear of the implant articular surfaces. Implant fracture and loosening due to cement failure has been reported.
7. The surgeon is to be thoroughly familiar with the implants and instruments, prior to performing surgery.
8. Patients should be warned of the impact of excessive loading that can result if the patient is involved in an occupation that includes substantial walking, running, lifting, or excessive muscle loading due to weight that place extreme demands on the knee and can result in device failure or dislocation.
9. Patient smoking may result in delayed healing, non-healing and/or compromised stability in or around the placement site.
10. The surgical technique should be followed. Deviations from the surgical technique could result in early loosening/failure of the device, or other adverse events as outlined in the following section. Clinical outcome may be affected by component positioning. Proper placement of the implant should take into consideration individual patient anatomy as well as surgeon preference. The surgical technique sets forth guidelines for placement of the knee system.

#### PRECAUTIONS

1. As with other surgical procedures, errors of technique are most likely when the method is being learned. To reduce these to a minimum, surgeons are required in the United States and strongly recommended throughout the world, to attend an Instructional Course on the Oxford Partial Knee before attempting the operation.
2. Biomet joint replacement prostheses provide the surgeon with a means of reducing pain and restoring function for many patients. While these devices are generally successful in attaining these goals they cannot be expected to withstand the activity levels and loads of normal healthy bone and joint tissue.
3. Accepted practices in postoperative care are important. Failure of the patient to follow postoperative care instructions involving rehabilitation can compromise the success of the procedure. The patient is to be advised of the limitations of the reconstruction and the need for protection of the implants from full load bearing until adequate fixation and healing have occurred. Excessive, unusual and/or awkward movement and/or activity, trauma, excessive weight, and obesity have been implicated with premature failure of the implant by loosening, fracture, dislocation, subluxation and/or wear. Loosening of the implants can result in increased production of wear particles, as well as accelerate damage to bone making successful revision surgery more difficult. The patient is to be made aware and warned in advance of general surgical risks, possible adverse effects as listed, and to follow the instructions of the treating physician including follow-up visits.

4. Specialised instruments are designed for Biomet joint replacement systems to aid in the accurate implantation of the prosthetic components. The use of instruments or implant components from any other systems can result in inaccurate fit, sizing, excessive wear and device failure.
5. Intraoperative fracture or breaking of instruments has been reported. Surgical instruments are subject to wear with normal usage. Instruments, which have experienced extensive use or excessive force, are susceptible to fracture. Surgical instruments should only be used for their intended purpose. Biomet recommends that all instruments be regularly inspected for wear and disfigurement.
6. All trial, packaging, and instrument components must be removed prior to closing the surgical site. Do not implant.

#### POSSIBLE ADVERSE EFFECTS

A time-course distribution of the adverse events reported in the clinical investigation of the Oxford Partial Knee using a standard open surgical technique is provided in Table 1.

Table 1 – Time-Course Distribution of Adverse Events reported in the clinical trial for the Oxford Partial Knee\* using a standard open surgical technique

| Adverse Events                        | Frequency |    |      |      |      |      |      | Percent of Population <sup>1</sup> (n=125) |       |
|---------------------------------------|-----------|----|------|------|------|------|------|--|-------|
|                                       | Visit     | IO | 6 mo | 1 yr | 2 yr | 3 yr | 4 yr |  | >5 yr |
| Local-Operative Site                  |           |    |      |      |      |      |      |  |       |
| Effusion                              |           |    |      | 1    |      |      |      | 0.8%                                       |       |
| Deep Infection                        |           |    |      |      | 1    |      |      | 0.8%                                       |       |
| Degeneration of contralateral condyle |           |    |      |      |      |      | 1    | 3  | 3.2%  |
| Loose body and/or osteophyte removal  |           |    | 1    |      | 2    |      |      | 1  | 3.2%  |
| Soft tissue damage                    |           | 2  |      |      |      |      |      |  | 1.6%  |
| Dislocation                           |           |    |      |      | 2    |      |      |  | 1.6%  |
| Component mal-alignment               |           |    | 1    |      |      |      |      |  | 0.8%  |
| Patella dislocation                   |           |    |      |      | 1    |      |      |  | 0.8%  |
| Component loosening                   |           |    |      |      |      | 1    | 2    | 3  | 4.8%  |
| Post-operative bone fracture          |           |    | 1    |      |      |      |      |  | 0.8%  |
| Trauma                                |           |    | 1    |      |      |      |      |  | 0.8%  |
| Mechanical symptoms                   |           |    |      | 1    |      |      |      |  | 0.8%  |
| Instability                           |           |    |      |      |      |      |      | 1  | 0.8%  |
| Persistent pain                       |           |    |      |      |      | 1    |      |  | 0.8%  |
| Wear of bearing due to osteophyte     |           |    |      |      |      |      | 1    |  | 0.8%  |
| Systemic                              |           |    |      |      |      |      |      |  |       |
| Development of rheumatoid arthritis   |           |    |      | 1    |      |      |      |  | 0.8%  |

\* Phase 2 device design

IO = intraoperatively

<sup>1</sup>All percentages for adverse events are based the number of occurrences reported in a patient population of 125 knee cases.

Those events listed in italics are considered device related events.

**Boldface** numbers represent revisions due to the given adverse event. One additional case was revised at 130 months post-operatively, cause unknown.

The following complications have also been reported in the clinical literature for partial and total knee arthroplasty designs and could potentially occur with the Oxford Partial Knee device.

1. Major surgical risks associated with anesthetic including brain damage, pneumonia, blood clots, heart attack, and death.
2. Cardiovascular disorders including venous thrombosis, pulmonary embolism, and myocardial infarction.
3. A sudden drop in blood pressure intraoperatively due to the use of bone cement.
4. Damage to blood vessels, hematoma, delayed wound healing and/or infection.
5. Temporary or permanent nerve damage may result in pain and numbness.
6. Material sensitivity reactions. Implantation of foreign material in tissues can result in histological reactions involving various sizes of macrophages and fibroblasts. The clinical significance of this effect is uncertain, as similar changes may occur as a precursor to or during the healing process.
7. Particulate wear debris and discoloration from metallic and polyethylene components of joint implants may be present in adjacent tissue or fluid. It has been reported that wear debris may initiate a cellular response resulting in osteolysis or osteolysis may be a result of loosening of the implant.
8. Early or late postoperative, infection, and allergic reaction.
9. Intraoperative bone perforation or fracture may occur, particularly in the presence of poor bone stock caused by osteoporosis, bone defects from previous surgery, bone resorption, or while inserting the device.
10. Loosening or migration of the implants can occur due to loss of fixation, trauma, malalignment, bone resorption, excessive activity.
11. Periarticular calcification or ossification, with or without impeding of joint mobility.
12. Inadequate range of motion due to improper selection or positioning of components.
13. Dislocation and subluxation due to inadequate fixation and improper positioning. Muscle and fibrous tissue laxity can also contribute to these conditions.
14. Fatigue fracture of components can occur as a result of loss of fixation, strenuous activity, malalignment, trauma, non-union, or excessive weight.
15. Fretting and crevice corrosion can occur at interfaces between components.
16. Wear and/or deformation of articulating surfaces.

Continued on next page.



17. Valgus-varus deformity.
18. Transient peroneal palsy secondary to surgical manipulation and increased joint movement has been reported following knee arthroplasty in patients with severe flexion and valgus deformity.
19. Patellar tendon rupture and ligamentous laxity.
20. Persistent pain.

**PATIENT SELECTION**

Positive selection factors to be considered include:

1. ACL and PCL functionally intact.
2. Cartilage and bone erosions limited to the anterior and middle parts of the medial compartment. The posterior part of the medial compartment and the lateral compartment having cartilage of normal thickness.
3. Medial collateral ligament not structurally shortened (i.e. varus deformity correctable).
4. Patellofemoral joint damage limited to (or greater on) the medial facets.
5. Fixed flexion deformity of less than 15 degrees.
6. Flexion possible to 110 degrees under anaesthetic.
7. Need to obtain pain relief and improve function.
8. Ability and willingness of the patient to follow instructions, including control of weight and activity level.
9. A good nutritional state of the patient.
10. The patient must have reached full skeletal maturity.

**CLINICAL STUDIES**

A prospective multi-site clinical investigation of the Oxford Partial Knee involving 125 knee devices in 107 patients (see Tables 2 and 3) was conducted in the United States to determine the safety and effectiveness of the device when implanted using a standard open surgical technique. All clinical results and adverse events for this investigation were derived from the Oxford Partial Knee Phase 2 device, a previous version of the current Phase 3 device, that had a single femoral component size, a universal (left and right) design tibial component of few sizes, and a universal design meniscal bearing component with extended sizes.

Table 2 – Patient Demographics for the Oxford Clinical Study (Phase 2 Device)

|                               | All Oxford Knees Enrolled   |
|-------------------------------|---|
| Total # Knees (# Patients)    | 125 (107)   |
| Mean Age in years (range)     | 63±10.6 (29–85)   |
| Sex                           | Males — 60 Females — 65   |
| Indications                   | Osteoarthritis — 114<br>Post-Traumatic Arthritis — 10<br>Avascular Necrosis — 1 |
| Side                          | Left — 56 Right — 69  |
| Compartment                   | Medial — 119 Lateral — 6  |
| Mean Height in Inches (range) | 67.0±3.9 (59–77)  |
| Mean Weight in Pounds (range) | 187±38.6 (105–256)  |

Table 3 – Device Accounting for the Oxford Clinical Study (Phase 2 Device) based on number of completed clinical follow-up examinations

|                                 | 6 months | 1 year | 2 year | 3 year | 4 year | 5 year |
|---------------------------------|----------|--------|--------|--------|--------|--------|
| <sup>1</sup> Theoretically Due  | 125      | 125    | 125    | 113    | 102    | 84     |
| <sup>2</sup> Deaths             | 0        | 0      | 1      | 2      | 2      | 2      |
| <sup>3</sup> Revisions          | 3        | 4      | 8      | 11     | 13     | 15     |
| <sup>4</sup> Expected           | 122      | 121    | 116    | 100    | 87     | 67     |
| <sup>5</sup> Clinical Follow-Up | 100      | 110    | 80     | 83     | 69     | 51     |
| <sup>6</sup> Percent Follow-up  | 82.0%    | 90.9%  | 69.0%  | 83.0%  | 79.3%  | 76.1%  |

- <sup>1</sup>Based on the cut-off date when the last patient enrolled reached their 2 year post-operative anniversary
- <sup>2</sup>Cumulative over time
- <sup>3</sup>Any component removed, cumulative over time
- <sup>4</sup>Theoretically Due – (Deaths + Revised)
- <sup>5</sup>Cases with complete clinical data (i.e., HSS, radiographic), obtained at the specified time point
- <sup>6</sup>Clinical Follow-Up / Expected

Each patient was evaluated pre-operatively, and at the immediate and 6, 12, and 24 month post-operative intervals, and annually thereafter until the last patient enrolled had achieved their 24 month follow-up. All operative and post-operative complications, device related or not, were recorded for patients enrolled into the investigation (see Table 1).

Clinical results were evaluated using the Hospital for Special Surgery (HSS) knee scoring system and radiographic data. At each follow-up visit an HSS knee score and anterior/posterior and lateral radiographs were obtained. Radiographs were reviewed by the implanting. See Table 4 for clinical study results.

A patient was defined as a success if they met all of the following criteria:

1. A Good/Excellent HSS score, i.e., > 70 points.
2. No radiolucent lines > 1 mm in width surrounding > 50% of the component after 1 year in-situ.
3. No progressive radiolucencies.
4. No revision/removal of any components.

Table 4 – Oxford Clinical Study Results\* (Phase 2 Device) using a standard open surgical technique

|   | Preop          | 1 year          | 2 years       | 3 years       | 4 years       | 5 years       |
|---|----------------|-----------------|---------------|---------------|---------------|---------------|
| Cases with complete HSS   | 123            | 110             | 80            | 83            | 69            | 51            |
| Average HSS Score   | 59.5           | 89.3            | 90.0          | 90.6          | 90.7          | 90.4          |
| <sup>1</sup> Cases Rated as Good/Excellent HSS                              | 20/123 (16.3%) | 105/110 (95.5%) | 77/80 (96.3%) | 82/83 (98.8%) | 64/69 (92.8%) | 50/51 (98.0%) |
| Femoral Lucencies = 1 mm  |                | 6/108 (5.5%)    | 2/80 (2.4%)   | 2/83 (2.4%)   | 2/68 (2.9%)   | 2/51 (2.9%)   |
| Tibial Lucencies = 1 mm   |                | 5/108 (4.6%)    | 6/80 (7.5%)   | 8/83 (9.6%)   | 7/68 (10.3%)  | 3/51 (5.9%)   |
| Number of G/E cases with radiolucent lines > 1 mm around > 50% of component |                | 0               | 0             | 0             | 0             | 1 (femoral)   |
| Number of G/E cases with progressive radiolucencies                         |                | 0               | 0             | 0             | 1 (tibial)    | 0             |
| <sup>2</sup> Revisions  |                | 4               | 8             | 11            | 13            | 15            |
| <sup>3</sup> Cumulative Survivorship  |                | 96.75%          | 93.34%        | 90.73%        | 88.83%        | 86.82%        |
| <sup>4</sup> Successful Cases   |                | 105             | 77            | 82            | 63            | 49            |
| <sup>5</sup> Percent Successful   |                | 92.5% (105/114) | 87.5% (77/88) | 87.2% (82/94) | 76.8% (63/82) | 74.2% (49/66) |

- \*Based on the cut-off date when the last patient enrolled reached their 2 year post-operative anniversary
- <sup>1</sup>Hospital for Special Surgery score > 70
- <sup>2</sup>Number of components removed at specified time point
- <sup>3</sup>Kaplan-Meier Life Table results
- <sup>4</sup>A successful case required a Good/Excellent HSS score, no revision/removal of any component, no radiolucent lines > 1 mm in width surrounding > 50% of the component, and no progressive radiolucencies.
- <sup>5</sup>Denominator includes cases with complete HSS and radiographic data, and revisions.

There were a total of 23 revisions reported for the Oxford study group (over a follow-up period of at least 9 years), with 8 of these occurring within the first 2 years of implantation. Of the 8 revisions reported at 2 years, 2 were for tibial bearing dislocation, 1 for patellar dislocation, 1 for infection, 1 for component malalignment, 1 for recurrent arthritis due to trauma, 1 for onset rheumatoid arthritis, and 1 for femoral loosening and fracture at the bone-cement interface. In all but 1 case the knees were revised to a total knee prosthesis. For the remaining 15 revisions reported after 2 years, 6 were due to loosening, 4 to progression of osteoarthritis in the lateral compartment, 1 to persistent pain, 1 to instability, 1 to impingement on an osteophyte and subsequent wear of the tibial bearing, 1 to impingement of an osteophyte on the femur, and 1 failed to report a reason. Revisions in this latter group occurred from 2 to 12 years post-operatively.

The survival rate for the Oxford Partial Phase 2 device study group at 2 years post-operatively is 93.38%, based on the endpoint of revision/removal of any component. Table 5 displays the Kaplan-Meier life table for survivorship through 8 years post-operatively for the Oxford study group. Survivorship rates for the study group are comparable to those rates seen in the literature for other partial knee devices and the rates seen in other studies of the Oxford Phase 2 device.

Table 5 – Survivorship for Oxford Clinical Study (Phase 2 Device)

| Interval Since Operation (years) | Number in Beginning of Interval | Number of Revisions at End of Interval | % Interval Survival <sup>1</sup> | % Cumulative Survival <sup>2</sup> | 95% Confidence Interval |
|----------------------------------|---------------------------------|--|----------------------------------|------------------------------------|-------------------------|
| 0-1                              | 125                             | 4                                      | 96.75%                           | 96.75%                             | (93.61 – 99.98)         |
| 1-2                              | 117                             | 4                                      | 96.52%                           | 93.38%                             | (88.95 – 97.82)         |
| 2-3                              | 109                             | 3                                      | 97.16%                           | 90.73%                             | (88.50 – 95.95)         |
| 3-4                              | 99                              | 2                                      | 97.91%                           | 88.83%                             | (83.08 – 94.57)         |
| 4-5                              | 90                              | 2                                      | 97.74%                           | 86.82%                             | (80.57 – 93.07)         |
| 5-6                              | 85                              | 0                                      | 100%                             | 86.82%                             | (80.57 – 93.07)         |
| 6-7                              | 65                              | 3                                      | 94.92%                           | 82.41%                             | (75.21 – 89.60)         |
| 7-8                              | 50                              | 1                                      | 97.87%                           | 80.65%                             | (73.35 – 87.95)         |

<sup>1</sup> Percent survival for that interval only, taken at the end of the interval.

<sup>2</sup> Percent cumulative survival taken at the end of the interval.

In addition, 2 year clinical data from 328 knee cases implanted with the current Phase 3 device, implanted using the minimally invasive surgical technique and minimally invasive surgical instruments specifically developed for the Phase 3 device, was collected from 3 European sites (2 U.K., 1 Holland). European clinical results were evaluated using the Knee Society Score (KSS) scoring system. At 2 years following surgery 5 of the 307 knees (1.6%) with available data had been revised (see Table 6).

Table 6 – Results at 2 years for Phase 2 Device using an open surgical technique and Phase 3 Device using a minimally invasive surgical technique

| Clinical Parameters                                      | Oxford Study Phase 2 N=125 knees      | Combined European Data* Oxford Phase 3 N=328 knees | European Site 1 Oxford Phase 3 N=208 knees | European Site 2 Oxford Phase 3 N=40 knees | European Site 3 Oxford Phase 3 N=80 knees |
|--|---------------------------------------|--|--|---|---|
| Revision Rate <sup>1</sup>                               | 6.8% (8/117)                          | 1.6% (5/307)                                       | 2.0% (4/196)                               | 2.7% (1/37)                               | 0% (0/74)                                 |
| Percent with a Good or Excellent Knee Score <sup>2</sup> | N=80<br>96.3% <sup>3</sup><br>(77/80) | N=271<br>83.0% <sup>4</sup><br>(225/271)           | N=160<br>83.1% <sup>4</sup><br>(133/160)   | N=37<br>86.5% <sup>4</sup><br>(32/37)     | N=74<br>81.0% <sup>4</sup><br>(60/74)     |

\*Combined data from European Site 1, Site 2, and Site 3.

European Site 1 = Nuffield Orthopaedic Centre (U.K.), Site 2 = Macclesfield Hospital (U.K.), and Site 3 = Groningen Hospital (Holland).

<sup>1</sup>Revision rate (%) at 2 years = cumulative number of revisions / (N - # deaths - # lost to follow up).

<sup>2</sup>Percent with Good or Excellent HSS or KSS knee score at 2 years.

<sup>3</sup>Based on HSS knee scoring system.

<sup>4</sup>Based on KSS knee scoring system.

#### BIOMET® OXFORD PARTIAL KNEE IMPLANTS IN THE MAGNETIC RESONANCE (MR) ENVIRONMENT

Biomet® Oxford Partial Knee implants are composed of non-ferromagnetic materials such as Titanium (Ti-6Al-4V), Cobalt Chrome (Co-Cr-Mo), Tantalum and ultra high molecular weight polyethylene (UHMWPE).

Biomet has performed bench testing and numerical simulations on Oxford Partial Knee implants in a Magnetic Resonance Imaging (MRI) environment. These tests determined the non-clinical effects of MRI based on scientifically relevant characteristics of the Oxford components.

#### MR Safety Information

The Oxford Partial Knee is determined to be MR Conditional in accordance to ASTM F2503-08 Standard Practice for Marking Devices and Other Items for Safety in the Magnetic Resonance Environment. MR Conditional refers to an item that has been demonstrated to pose no known hazards in a specified MR environment with specified conditions of use, as stated below.

Safety information for the use of MRI procedures (i.e. imaging, angiography, functional imaging, spectroscopy, etc.) pertains to shielded MRI systems under the following specifications:

- Static magnetic field of 1.5-Tesla (1.5T) and 3.0-Tesla (3.0T)
- Spatial gradient field of 2500-Gauss/cm or less
- Maximum MR system reported, whole-body-averaged specific absorption rate (SAR) of 2-W/kg for 15 minutes of scanning
- Normal mode of the MR system
- The effects of using MR conditions above these levels have not been determined
- The effects of local RF transmit coils have not been tested and are not recommended in the area of the implant
- Per good clinical practices, the patient's legs should not touch each other and arm and legs should not touch the side of the bore during scanning

#### MR Information

##### 1.5T MR system

64 MHz, GE Signa whole body coil from GE Signa MR System, model number 46-258170G1 and serial number 10146MR9; the magnet producing the static field was not present. RF power was applied continuous wave (CW) with an HP8640B (serial number 1716A06448) preamplifier and an ENI power amplifier (model 3200L, serial number 469).

- A temperature rise of 1.5 °C or less was measured at a maximum whole body averaged specific absorption rate (SAR) of 2 W/kg for 15 minutes of RF power application.

##### 3.0T MR system

128MHz, GE Signa HDx 3T, Software Version=14\LX\MR Software release.14.0.M5A.0828.b, General Electric Healthcare, Milwaukee, WI. active-shielded, horizontal field scanner.

- A temperature rise of 1.4 °C or less was measured at a maximum whole body averaged specific absorption rate (SAR) of 2 W/kg for 15 minutes of RF power application.

#### Image Artifacts

MR image quality may be compromised if the area of interest is in the same area or relatively close to the position of the device. Distortion extended as much as 8 cm from the implant in image distortion tests performed according to ASTM F2119 in a 3.0 T GE Signa HDx MR system (Software Version 14\LX\MR Software release.14.0.M5A.0828.b). Therefore, it may be necessary to optimize MR imaging parameters for the presence of these implants.

**Other:** Testing indicated no known risks of magnetically induced displacement force or torque.

#### STERILITY

Prosthetic components are sterilised by exposure to a minimum dose of 25 kGy of gamma radiation. Single Use Only. Do Not Reuse. Do not resterilize. Do not use any component from an opened or damaged package. Do not use implants after expiration date.

Caution: Federal law (USA) restricts this device to sale by or on the order of a physician.

#### Manufactured and Distributed by:

Biomet UK Ltd.  
Waterton Industrial Estate  
Bridgend CF31 3XA, UK

#### Distributed in the United States by:

Biomet Orthopedics,  
56 East Bell Drive  
P.O. BOX 587  
Warsaw, IN 46581 USA

CE mark on the package insert (IFU) is not valid unless there is a CE Mark on the product label.







## References

1. Goodfellow, J. *et al.* The Mechanics of the Knee and Prosthesis Design. *The Journal of Bone and Joint Surgery [Br]*. 60-B:358–69, 1978.
2. Argenson, J. *et al.* Polyethylene Wear in Meniscal Knee Replacement. A One to Nine-year Retrieval Analysis of the Oxford Knee. *The Journal of Bone and Joint Surgery [Br]*. 74-B:228–32, 1992.
3. Psychoyios, V. *et al.* Wear of Congruent Meniscal Bearings in Unicompartamental Knee Arthroplasty—A Retrieval Study of 16 Specimens. *The Journal of Bone and Joint Surgery [Br]*. 80-B:976–82, 1998.
4. White, S. *et al.* Anteromedial Osteoarthritis of the Knee. *The Journal of Bone and Joint Surgery [Br]*. 73-B:582–86, 1991.
5. Murray, D. *et al.* The Oxford Medial Unicompartamental Arthroplasty, a Ten Year Survival Study. *The Journal of Bone and Joint Surgery [Br]*. 80-B:983–9, 1998.
6. Weale, A. *et al.* Does Arthritis Progress in the Retained Compartments after Oxford Medial Unicompartamental Arthroplasty? *Journal of Bone and Joint Surgery [Br]*. 81-B:783–9, 1999.
7. Price, A. *et al.* Ten Year Survival Results of Oxford Mobile Bearing Unicompartamental Knee Arthroplasty in Young Patients. I.S.T.A. Chicago, 1999.
8. Bankston, A. *et al.* Comparison of Polyethylene Wear in Machined Versus Moulded Polyethylene. *Clinical Orthopaedics and Related Research*. 317:37–43, 1995.
9. Kendrick, B. *et al.* Polyethylene Wear of Mobile-bearing Unicompartamental Knee Replacement at 20-years. *The Journal of Bone and Joint Surgery [Br]*. 93-B:470–5, 2010.
10. Pandit, H. *et al.* Unicompartamental Knee Replacement for Patients with Partial Thickness Cartilage Loss in the Affected Compartment. *The Knee*. 18(3):168–71, 2011.
11. Keyes, G. *et al.* The Radiographic Classification of Medial Gonarthrosis. Correlation with Operation Methods in 200 Knees. *Acta Orthopaedica Scandinavica*. 63 (5):497–501, 1992.
12. Gibson, P. *et al.* Stress Radiography in Degenerative Arthritis of the Knee. *The Journal of Bone and Joint Surgery [Br]*. 68-B:608–9, 1986.
13. Berend, K. *et al.* Does Preoperative Patellofemoral Joint State Affect Medial Unicompartamental Arthroplasty Survival? AAOS Poster No. P204. February 2011.
14. Berend, K. *et al.* Obesity, Young Age, Patellofemoral Disease and Anterior Knee Pain: Identifying the Unicompartmental Arthroplasty Patient in the United States. *Orthopedics*. 30(Suppl 5):19–23, 2007.
15. Kang, S. *et al.* Pre-operative Patellofemoral Degenerative Changes Do Not Affect the Outcome After Medial Oxford Unicompartamental Knee Replacement. *The Journal of Bone and Joint Surgery [Br]*. 93-B:476–8, 2010.
16. Pandit, H. *et al.* Unnecessary Contraindications for Mobile-bearing Unicompartamental Knee Replacement. *The Journal of Bone and Joint Surgery [Br]*. 93-B:622–8, 2011.
17. Tibrewal, S. *et al.* The Radiolucent Line Beneath the Tibial Components of the Oxford Meniscal Knee. *The Journal of Bone and Joint Surgery*. 66-B:523–8, 1984.
18. Gunther TV, *et al.* Lateral Compartment Arthroplasty with the Oxford Meniscal Knee. *Knee* 1996; 3:33-39.
19. Fawzy, E, *et al.* Determination of femoral component size in unicompartamental knee replacement. *The Knee* 15 (2008) 403–406.
20. Gulati, A., *et al.* “The incidence of physiological radiolucency following Oxford unicompartamental knee replacement and its relationship to outcome.” *Bone & Joint Journal* 91.7 (2009): 896–902.

All content herein is protected by copyright, trademarks and other intellectual property rights, as applicable, owned by or licensed to Zimmer Biomet or its affiliates unless otherwise indicated, and must not be redistributed, duplicated or disclosed, in whole or in part, without the express written consent of Zimmer Biomet.

This material is intended for health care professionals, the Zimmer Biomet sales force and Zimmer Biomet employees. Distribution to any other recipient is prohibited.

For product information, including indications, contraindications, warnings, precautions, potential adverse effects and patient counseling information, see the package insert and [www.zimmerbiomet.com](http://www.zimmerbiomet.com)

Zimmer Biomet does not practice medicine. This technique was developed in conjunction with health care professionals. This document is intended for surgeons and is not intended for laypersons. Microplasty instruments described in this surgical technique are intended to facilitate implantation of the Oxford Partial Knee components. Each surgeon should exercise his or her own independent judgment in the diagnosis and treatment of an individual patient, and this information does not purport to replace the comprehensive training surgeons have received.

As with all surgical procedures, the technique used in each case will depend on the surgeon’s medical judgment as the best treatment for each patient. Results will vary based on health, weight, activity and other variables. Not all patients are candidates for this product and/or procedure.

Caution: Federal (USA) law restricts this device to sale by or on the order of a surgeon. Rx only.

©2019 Zimmer Biomet



**ZIMMER BIOMET**  
Your progress. Our promise.®

0297.3-US-en-REV0519

**Legal Manufacturer**  
Biomet UK Limited  
Waterton Industrial Estate  
Bridgend  
CF31 3XA  
UK

[oxfordpartialknee.com](http://oxfordpartialknee.com)